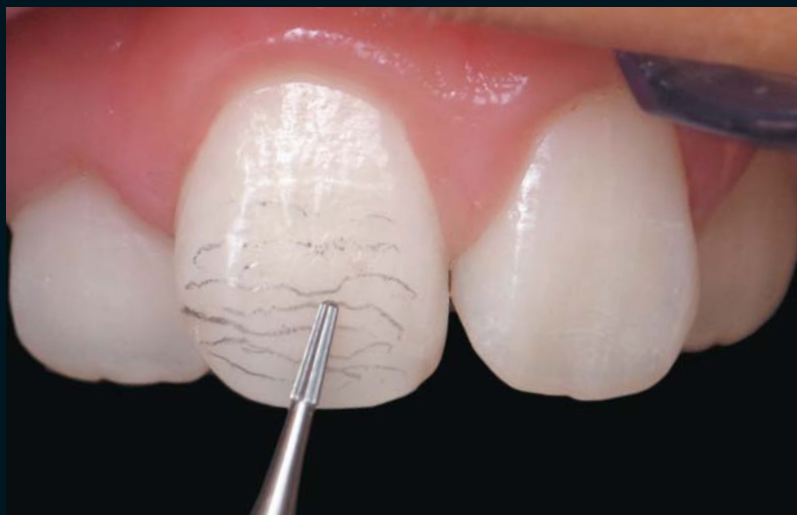

# FINISHING AND POLISHING TECHNIQUES: DIRECT COMPOSITE RESIN RESTORATIONS

James H. Peyton, DDS\*



*Contemporary clinicians are responsible for delivering realistic restorations that closely resemble the existing natural tooth structures. In order to achieve such aesthetic results, the use of exemplary materials is required. Recent advancements in composite resin systems have improved the practitioner's ability to deliver optimal results using chairside techniques. The incorporation of a precise finishing and polishing protocol further allows the clinician to seal the restoration and maintain natural surface luster and contour. This article presents the necessary finishing and polishing protocol to ensure long-term aesthetic results.*

### Learning Objectives:

This article presents the clinical protocol for finishing and polishing direct composite resins. Upon reading this article, the reader should:

- Understand the role of finishing and polishing on the definitive restoration.
- Be aware of the protocol associated with development of optimal tooth morphology using finishing and polishing techniques.

*Key Words: finishing, polishing, tertiary anatomy, direct, primary anatomy*

---

\*Private practice, Bakersfield, California; Part-time clinical instructor: UCLA Center for Esthetic Dentistry, Los Angeles, California and the Fahl Institute, Curitiba, Brazil; Esthetic Professionals Education Center, Tarzana, California.

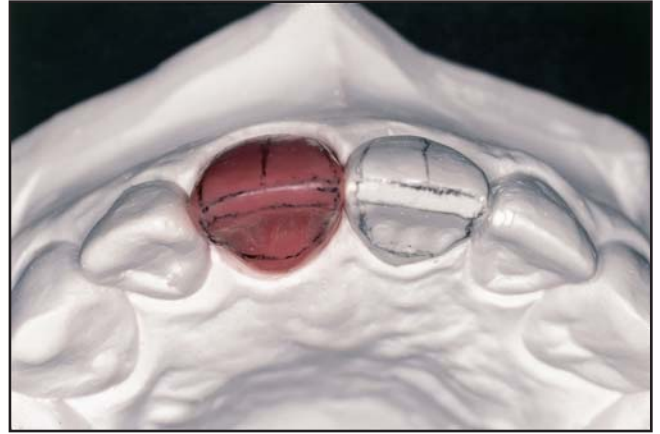**James H. Peyton, DDS, 2212 Truxtun Avenue, Bakersfield, CA 93301**  
Tel: 661-323-1888 • Fax: 661-323-0188 • E-mail: [UCLAteeth@aol.com](mailto:UCLAteeth@aol.com)

Cosmetic dentists are expected to create realistic restorations that mimic natural tooth structures. Unlike porcelain (indirect) restorations, a composite restoration is created entirely by the practitioner. The clinician determines the color, shape, and contour of the restoration. Like a sculptor or a painter, the dentist is an artist whose work is on display every time the patient smiles.

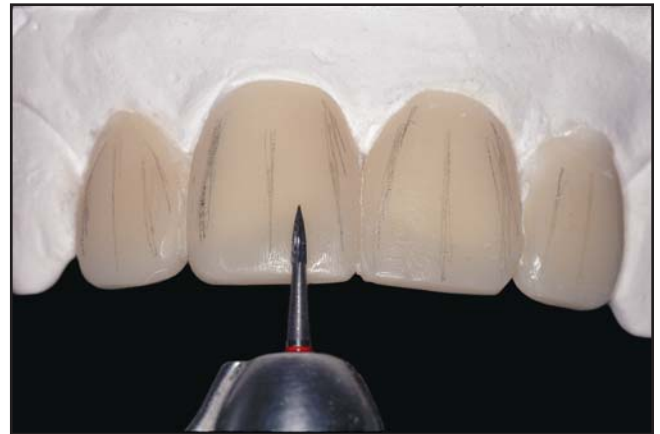Similar to a sculptor who studies every aspect of the human anatomy in creating a masterpiece, a dentist must also be acutely aware of anatomy. The definitive surface details of the restoration must demonstrate exact light reflective surfaces, symmetrical embrasures, surface texture, and proportion. Development of an acceptable polish also influences the durability of the restoration, improves its marginal integrity, and decreases plaque formation. This article will review the clinical protocol for improved finishing and polishing techniques following application of direct composite resin restorations.

### Basic Tooth Anatomy

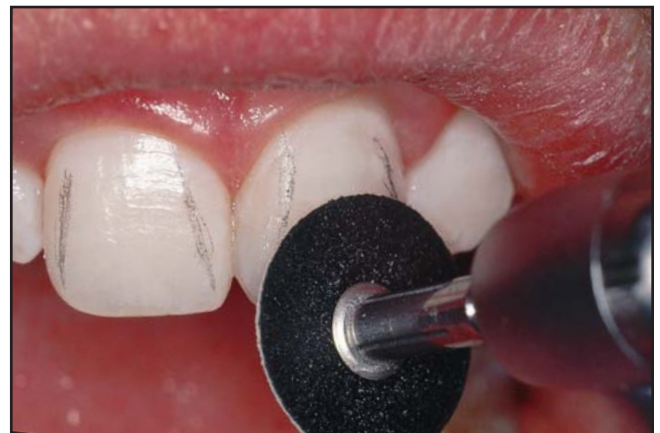Line angles are clearly defined by the light reflective surface. If wide or narrow line angles are present, the tooth will appear overly large or small. In certain instances where the tooth space is not ideal, use of various line angles can allow the clinician to create an illusion of appropriate size in a nonideal area.<sup>1</sup> A tooth waxup exercise can be used to practice the replacement of missing tooth structures with the proper anatomy (Figure 1). In this exercise, the incisal edge is created first, followed by the mesial and distal line angles that simulate the light reflective surfaces. The line angles form a shell, within which the tooth is formed. This will help the dentist understand the primary and secondary anatomy using a simple and practical restorative material. Composite mock-ups can then be used to instruct clinicians on how to accurately contour composites (Figure 2). The composite mock-up exercise can be performed on a typodont or on extracted teeth.<sup>2</sup> “Hands-on” direct composite resin workshops where these techniques can be practiced and critiqued are highly recommended. This article will discuss the protocol used



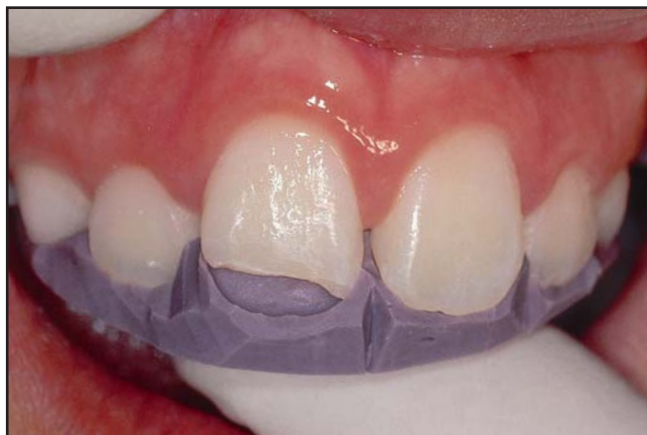**Figure 1.** Preoperative waxup following creation of the incisal edge and interproximal embrasures.



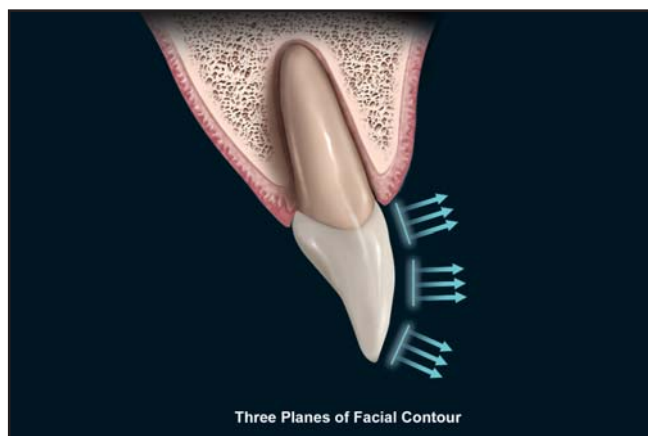
**Figure 2.** Appearance of the composite mock-up placed on a stone model to provide instruction on composite contouring.



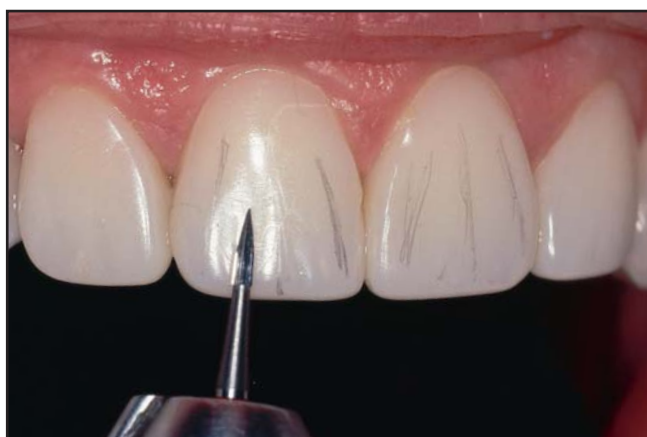**Figure 3.** A coarse finishing disk was used to establish the restoration's primary anatomy.



**Figure 4.** The putty matrix was used to establish the incisal and lingual contours.



**Figure 5.** With the carbides or coarse disk, the gingival, central, and incisal planes are shaped.



**Figure 6.** Creation of the secondary anatomy can be performed with a small flame-tip carbide bur.

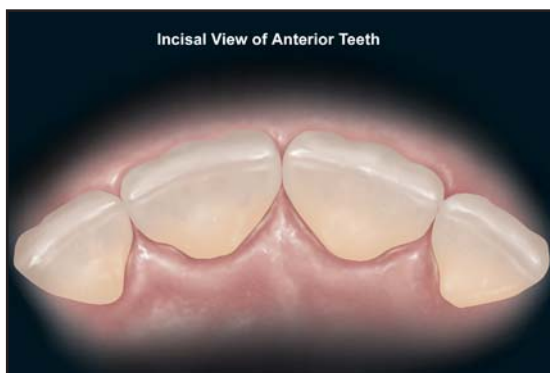
to achieve the proper finish and polish by creating appropriate primary, secondary, and tertiary anatomy on a composite restoration.

### Establishment of Primary Anatomy

The first step in finishing and polishing is establishing primary tooth anatomy (ie, the basic contour or shape of the tooth) using a coarse disk once the resin restoration is built up to final contour (Figure 3).<sup>3</sup> The coarse disk can be used to remove the composite and create an even and flat surface. A flexible disk (eg, Sof-Lex XT, 3M ESPE, St. Paul, MN; FlexiDiscs, Cosmedent, Chicago, IL) can then be used to create a smooth interproximal contour or an incisal embrasure (Table).

The coarse disks are used at low speed without irrigation or polishing pastes. The rough surfaces that are left following this phase in the polishing procedure can then be polished once it is ascertained that the appropriate primary anatomy is created. If a large excess of material needs to be contoured, it may be necessary to first use high-speed rotary carbide burs (eg, 7901, OS1, OS2, ET9, Brasseler USA, Savannah, GA; H157-010, Axis Dental, Irving, TX) under water irrigation to approximate the final contour.

The use of a silicone putty matrix during the composite layering process can further facilitate the finishing and polishing procedure (Figure 4).<sup>4</sup> This tool minimizes the amount of lingual finishing required and allows development of a moderately accurate incisal edge contour. Since the interproximal embrasure is difficult to correct, development of an accurate contour in this region will facilitate creation of an accurate restoration. While placement of additional composite on the facial aspect is necessary to establish contour, a large excess of resin will require additional adjustment during the finishing and polishing stage. The placement of pits and voids should also be avoided on the composite surface by etching well beyond the margin and to add composite in uniform layers. Care should be taken during this process to avoid incorporation of air into the composite restoration.



**Figure 7.** Illustration demonstrates the incisal aspect of the anterior dentition.

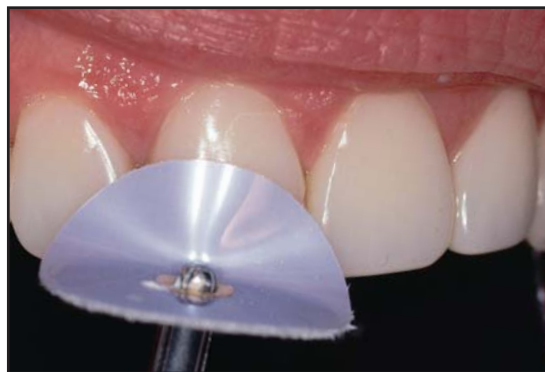### **Finishing and Polishing Sequence**

Once the incisal edge length is determined and established, the correct width (ie, 75% to 80% of the length) of the restoration should be verified. Using the adjacent teeth (if available) or Golden Proportion measurements, the proper width of the dentition can be ascertained. At that point, the lingual aspect can be adjusted using a football-shaped carbide bur. The facial contour can be developed using rotary instrumentation to ensure that the tooth has three planes. The tooth surface should not be completely flat or totally rounded (Figure 5).<sup>5</sup> The gingival and mid-tooth planes of the facial aspect can then be developed. Care should be taken to ensure the development of a smooth surface and marginal integration. The incisal plane of the facial aspect is the final region that should be finished. The definitive contour of the embrasure spaces can then be refined. The incisal embrasure should increase distally from the central incisor.

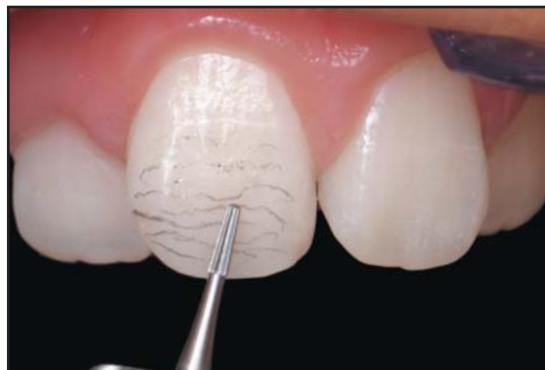### **Secondary Anatomy**

Once the primary anatomy is established, the secondary anatomy can be created by tracing the heights of contour on the adjacent tooth structures. The clinician can then establish the necessary anatomy that requires duplication (Figure 6). When the adjacent tooth is not ideal, then the estimated position of the line angles can be traced out in pencil.<sup>5</sup>

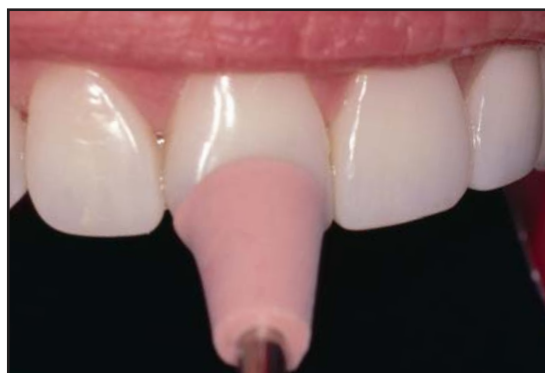The height of contours that should be placed on the bonded tooth should be drawn, in pencil, prior to finishing. Thin flexible disks can then be used on the



**Figure 8.** A super-fine gloss finish can be achieved with a buff wheel and polishing paste.

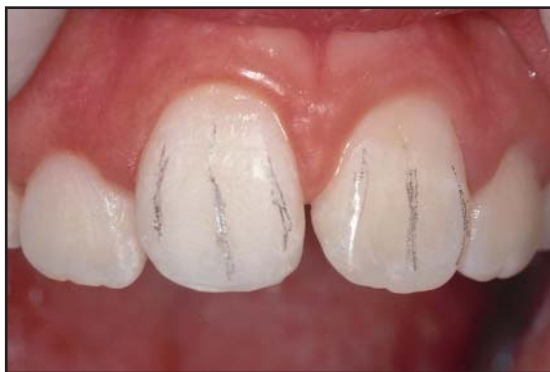

**Figure 9.** A tapered, round-end carbide bur was used to create the perikimata.

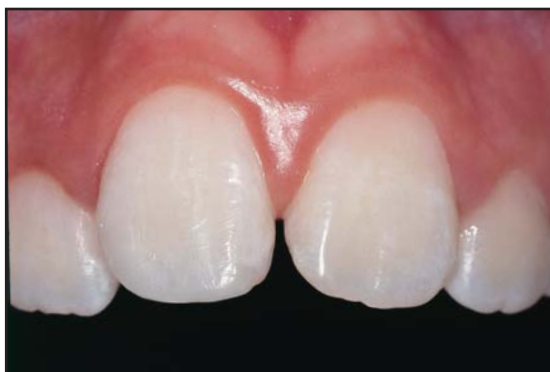

**Figure 10.** A high polish was achieved using rubber cups and points.

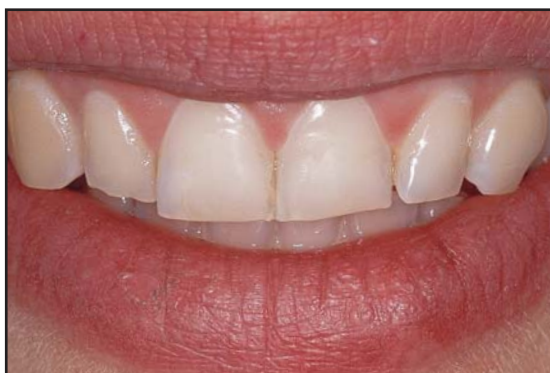mesial line angles, followed by contouring of the distal line angles<sup>6</sup>. Flame-tip carbide burs (eg, #7901, Brasseler USA, Savannah, GA; H 246-009, Axis Dental, Irving, TX) can be used to create the facial lobes and depression areas. It is, however, critical to create a depression area rather than a sharp line by carefully passing the flame-tip carbide bur back and forth to



**Figure 11.** Lines were drawn on the teeth to define the line angles and to create dentinal lobes.

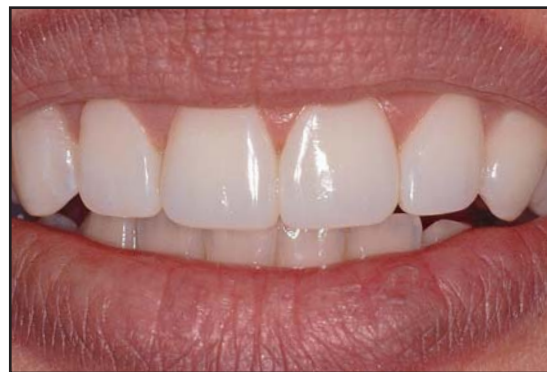

**Figure 12.** Postoperative appearance of the restoration. With the correct finishing and polishing techniques, a mirror image of the adjacent natural tooth was created.



**Figure 13.** Preoperative view of the severely worn incisal edges and dark teeth.

preserve the heights of contour.<sup>7</sup> By observing the incisal edge, the clinician can determine if the desired lobe formation is achieved (Figure 7). If the tooth requires additional surface texture, a fine diamond bur can be used at a low speed from the mesial aspect to the distal. A medium rubber cup, a fine rubber cup, and a felt buff wheel can be used with a polishing paste



**Figure 14.** A buff wheel and polishing paste were used to achieve a super-fine gloss finish.

(eg, Enamelize, Cosmedent, Chicago, IL; Diamond Polish, Ultradent Products, South Jordan, UT; Shammy Bright, Axis Dental, Irving, TX) (Figure 8).

### Tertiary Anatomy

Fine-tuning of the restoration's surface is generally performed during a follow-up appointment. Direct resin veneers require additional time, and there is no need to rush through this important step. The patient may require modifications to the occlusion or contour, and the clinician can then visualize the tertiary anatomy (ie, textured or smooth) needed.

### Textured Surface

To create a youthful appearance that is characterized by surface irregularities (ie, the overall shape of the tooth is correct, but small surface changes are evident in the light reflective surfaces),<sup>8</sup> a coarse disk can be applied once

## Table

### Finishing and Polishing Armamentarium

- Polishing Disks (eg, Sof-Lex XT, 3M ESPE, St. Paul, MN; FlexiDiscs, FlexiBuff, Cosmedent, Chicago, IL)
- Carbide Burs (eg, 7901, OS1, OS2, ET9, Brasseler USA, Savannah GA)
- Rubber Cups, Points, and Wheels (eg, P0735, Axis Dental, Irving, TX; Jiffy Polishing System, Ultradent Products, South Jordan, UT)
- Polishing Paste (Diamond Polish, Ultradent Products, South Jordan, UT)

the correct anatomy has been achieved. The buff wheel and polishing paste are subsequently applied. If a high polish has been achieved, a tapered, round-end carbide bur (eg, OS2, Brasseler USA, Savannah, GA; H1157-FG, Axis Dental, Irving, TX) can be used at a low speed, applied back and forth in a horizontal direction using a "feather touch" to create the perikimata (Figure 9). Polishing paste can then be applied with the buff wheel to recreate the high polish. The small uniform scratches will remain to provide a more natural appearance.

### Smooth Surface

If the adjacent teeth are very smooth and possess minimal characterization, the complete disk sequence (ie, coarse, medium, fine, and super-fine) can be applied to ensure optimal surface luster. This will eliminate all the surface scratches and the surface will be smooth and flat. Dentinal lobes can then be created and depression areas can be repolished prior to the application of felt brush wheels and polishing paste for the final gloss.

### High-Gloss Surface Polish

Development of a high-luster polish depends on the composite's particle size. Microfilled and nanofilled composites, due to their small particle size, are easy to polish. A high polish can be rapidly obtained using a rubber polishing cup (Figure 10). The buff wheel and polishing paste can be applied to develop an "enamel-like," high-gloss surface polish. Hybrid composites with larger particle size (and, to a lesser extent, microhybrids) are more difficult to polish. Some of the newer, diamond-impregnated, rubber polishing systems are necessary (eg, Pogo, Dentsply Prosthetics, Milford, DE; Astropol, Ivoclar Vivadent, Amherst, NY; Diacomp, Brasseler USA, Savannah, GA).<sup>9</sup> Additional time and effort may be needed to obtain the desired result. It is sometimes helpful to go through all grits of polishing disks and rubber wheels from coarse to super-fine. The final polish of a hybrid is also obtained with a buff wheel and polishing paste. Another method to achieve a high final polish is to use a silicone carbide impregnated brush (eg, Jiffy Brush, Ultradent Products, South Jordan, UT). Care should

be taken during the polishing procedure not to lose the anatomical features that were carefully created during this final step. The restoration should then be evaluated from several different angles to ensure that all necessary modifications are made to enhance the final result (Figures 11 through 14).

### Conclusion

A successful anterior direct resin restoration must possess the proper anatomy and appropriate surface characterizations. Light should reflect off the heights of contour to match the adjacent teeth. A composite restoration should be created using the finest materials, the correct shades, appropriate tints and opaquers, and be properly layered with dentin and enamel shades. If the restoration does not have the correct contours and appropriate polish, the restoration will not have a natural appearance. It is, therefore, important to be able to reproduce the basic tooth anatomy and characterizations to create an aesthetic restoration. The ideal composite restoration should be indistinguishable from the natural tooth. If this can be accomplished, then the clinician can truly be considered an artist and can provide a valuable service to his or her patients.

### References

1. Rufenacht C. *Fundamentals of Esthetics*. Carol Stream, IL: Quintessence Publishing; 1990:87-94,127-131.
2. Fahl NJ. Course notes from the Fahl Institute, Curitiba, Brazil. Anterior Direct Composite Course. 2001-2004.
3. Fahl NJ. Predictable aesthetic reconstruction of fractured anterior teeth with composite resins: A case report. *Pract Periodont Aesthet Dent* 1996;8(1):17-30.
4. Behle C. Placement of direct composite veneers utilizing a silicone build-up guide and intraoral mock-up. *Pract Periodont Aesthet Dent* 2000;12(3):259-266.
5. Blitz N. *Diagnosis and Treatment Evaluation in Cosmetic Dentistry. A Guide to Accreditation Criteria*. American Academy of Cosmetic Dentistry. Madison, WI.
6. Peyton JH. Direct restoration of anterior teeth: Review of the clinical technique and case presentation. *Pract Proced Aesthet Dent* 2002;14(3):203-210.
7. Fahl NJ. *Advanced Color Stratification and Finishing*. Clinical Guidelines, 3M Filtek A110. 2000. Mahwah, NJ: Montage Media Corp; 2000:11-16.
8. Baratieri LN. *Aesthetics: Direct Adhesive Restoration on Fractured Anterior Teeth*. Carol Stream, IL: Quintessence Publishing; 1998.
9. Miller M. *Contouring and Polishing Resin-Based Materials. Reality; The Techniques* 2003;1:23-29.

# CONTINUING EDUCATION (CE) EXERCISE No. 11

To submit your CE Exercise answers, please use the answer sheet found within the CE Editorial Section of this issue and complete as follows: 1) Identify the article; 2) Place an X in the appropriate box for each question of each exercise; 3) Clip answer sheet from the page and mail it to the CE Department at Montage Media Corporation. For further instructions, please refer to the CE Editorial Section.

The 10 multiple-choice questions for this Continuing Education (CE) exercise are based on the article "Finishing and polishing techniques: Direct composite resin restorations," by James H. Peyton, DDS. This article is on Pages 293-298.

**1. When finishing and polishing a composite, the first step is to:**

- a. Establish primary anatomy.
- b. Establish secondary anatomy.
- c. Obtain a high-gloss finish.
- d. Use a rubber wheel.

**2. The use of a putty matrix is important because it:**

- a. Creates a high-gloss surface finish.
- b. Strengthens the restoration.
- c. Minimizes the finishing and polishing by creating the lingual surface and incisal edge contour.
- d. Decreases polymerization shrinkage.

**3. According to the principles of "Golden Proportion," the width of a central incisor should be:**

- a. Box-like in form.
- b. Very wide.
- c. Approximately 50% of the length.
- d. Approximately 75% to 80% of the length.

**4. Reviewing dental anatomy and practicing tooth waxups are helpful to allow the dentist to:**

- a. Correctly contour the restorations.
- b. Impress your lab technicians.
- c. Make stronger composite fillings.
- d. Build vocabulary skills and increase manual dexterity.

**5. A highly textured enamel surface would usually be found on a:**

- a. Bruxism patient.
- b. Bulimic patient.
- c. Pediatric patient.
- d. Geriatric patient.

**6. To make teeth look natural, the incisal embrasures should:**

- a. Gradually get smaller going from the central incisor distally.
- b. Gradually get larger going from the central incisor distally.
- c. Be completely open.
- d. Be completely closed.

**7. The most predictable instrument to create an even flat surface is with a:**

- a. Football-shaped carbide.
- b. Coarse finishing disk.
- c. Flame-tip carbide.
- d. Rubber wheel.

**8. A diagnostic waxup is helpful because it:**

- a. Is made of wax.
- b. Involves your dental auxiliaries.
- c. Impresses the patient.
- d. Establishes ideal contours.

**9. The ability to obtain a high-gloss finish on a composite is dependent upon:**

- a. The particle size.
- b. The bonding agent.
- c. Using a coarse disk.
- d. Using a flame-tip carbide.

**10. The basic contour and shape of the tooth is called the:**

- a. Bulk build-up.
- b. Primary anatomy.
- c. Secondary anatomy.
- d. Tertiary anatomy.