

# DIRECT RESTORATION OF ANTERIOR TEETH: REVIEW OF THE CLINICAL TECHNIQUE AND CASE PRESENTATION

James H. Peyton, DDS\*

*Direct composite resin bonding procedures are growing in popularity as conservative and predictable restorative treatment alternatives. An understanding of the fundamental layering, contouring, and polishing principles is paramount to the success of any direct composite restoration; this awareness can be subsequently applied to indirect restorations and significantly enhance laboratory/clinician communication. This article presents a clinical technique that describes the incremental placement of direct resin veneers on a typodont and demonstrates the application of these procedures on an actual clinical case.*

**Key Words:** composite, incremental, direct, resin

In recent years, significant improvements in composite resin technology have occurred. Various new composite resin systems (eg, Esthet-X, Dentsply/Caulk, Milford, DE; Point 4, Kerr/Sybron, Orange, CA; Renamel, Cosmedent, Chicago, IL) have been developed in response to clinicians' increasing demand for materials with enhanced physical properties and aesthetics.<sup>1</sup> These contemporary material formulations contain more diverse ranges of shades with greater mechanical properties.<sup>2-4</sup>

The development of these composite materials has provided clinicians with the ability to directly restore fractured and misshapen teeth and to repair defective enamel.<sup>5</sup>

\*Clinical Instructor, UCLA Center for Esthetic Dentistry, Los Angeles, California; private practice, Bakersfield, California.

James H. Peyton, DDS  
2005 19th Street  
Bakersfield, CA 93301

Tel: 661-323-1888  
Fax: 661-323-0188  
E-mail: UCLAteeth@aol.com

Composite resins can be used in direct procedures to successfully restore function and aesthetics, and they are often less abrasive on opposing teeth than porcelain.<sup>6-9</sup> Direct resin veneers are recommended as an immediate treatment option for patients who will eventually require extensive restoration (eg, orthodontic procedures). Since preparation for direct veneers is often conservative, and minimal — if any — tooth structure is removed, these materials can often be used to augment the existing tooth structure with clinically reversible results. Missing tooth structure can be corrected with direct resin, and incisal edge length can be easily added or reduced. The use of composite restorations is also indicated for the treatment of younger patients with immature gingival crests. Utilization of this treatment modality eliminates laboratory fees from the overall cost of restorative treatment, and patient expenditures are further reduced by the clinician's ability to (potentially) complete restorations in one visit. Limitations associated with direct resin veneer restorations include increased chairtime and the

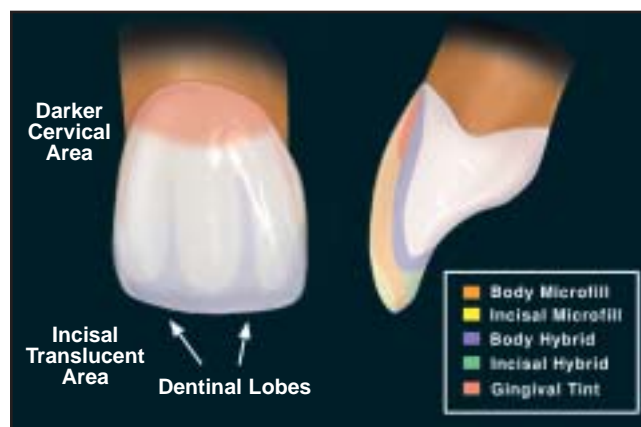


Figure 1. Illustration demonstrates the various composite layers used in this laboratory exercise.

necessity for a high-quality aesthetic composite resin system.<sup>2</sup> A comprehensive understanding of material strengths and characteristics is required for successful application, and the oral habits (ie, bruxism or similar parafunctional habit) of the patient must be identified prior to treatment.

Using a typodont, this article reviews a basic technique for sculpting direct resin veneers. A step-by-step incremental buildup technique is used to demonstrate the composite layering procedures. A clinical case of 10 direct resin veneers is also presented to demonstrate the application of this technique for aesthetic and functional results.

### Composite Resin Selection

#### Hybrid Composites

In extensive restorations, the hybrid composite is the first layer that contacts the natural tooth structure (ie, Renew, Bisco, Schaumburg, IL; Charisma, Hereaus Kulzer, Armonk, NY; Filtek Z250, 3M ESPE, St. Paul, MN). This material is highly filled with ground particles (ie, quartz, strontium, heavy metal glasses that contain barium).<sup>10</sup> This is the material of choice for posterior restorations, and it provides an excellent underlying layer when a microfill is used as the surface layer on anterior restorations.<sup>11</sup> Hybrid composite materials can be successfully used for the restoration of Class IV anterior restorations and any restoration where a high amount of stress is anticipated.<sup>12</sup> The radiopacity of hybrid materials is particularly important during the placement of Class II posterior

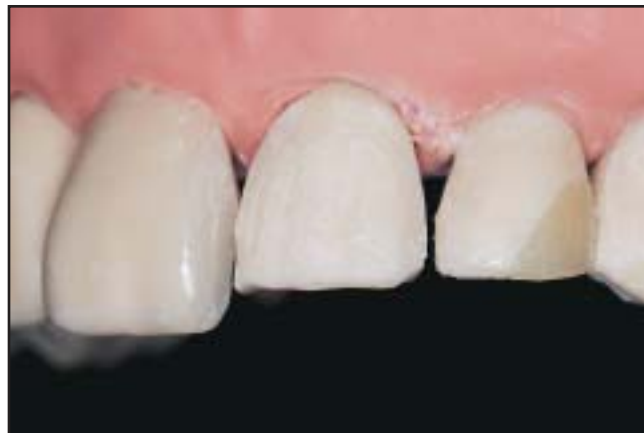

Figure 3. A model is used to illustrate the preparation of typodont teeth #9, #10, and #11 for subsequent placement of direct resin veneers.

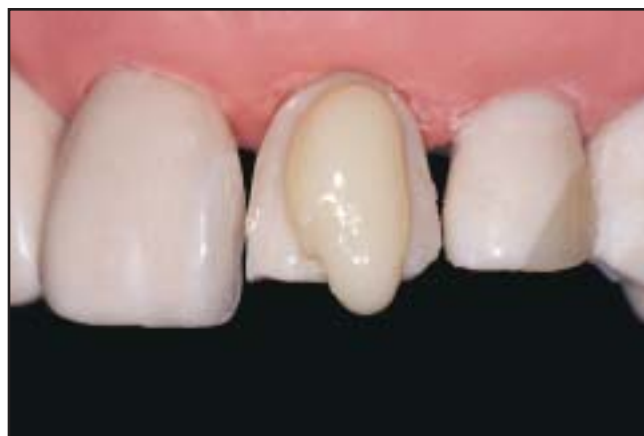

Figure 4. A cylinder of hybrid composite is placed over the facial surface following placement of the adhesive agent.

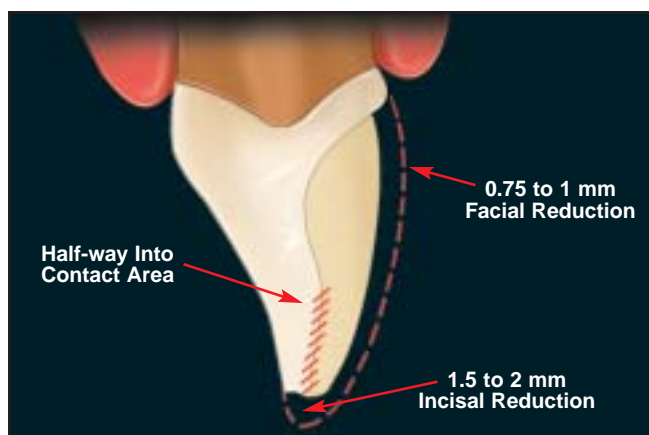
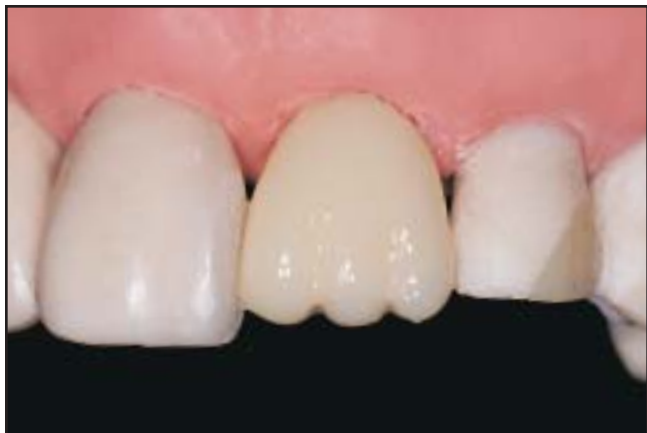

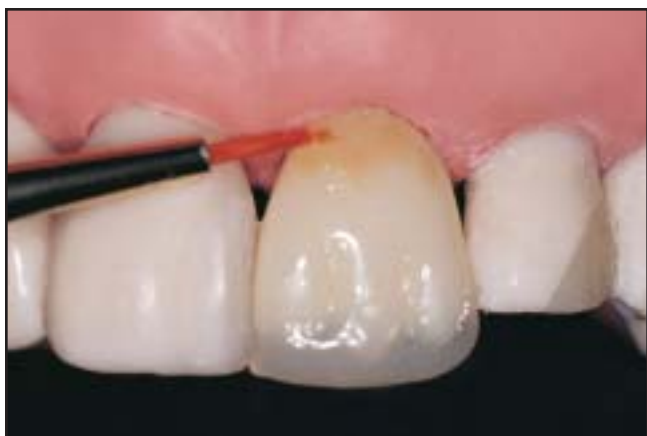Figure 2. Approximately 1 mm was removed from the facial aspect and 1.5 mm was reduced off the incisal edge for instructional purposes.

restorations to radiographically determine if the margin is sealed or becomes decayed in the future. These restorations are contraindicated, however, for the treatment of Class III and Class V defects and in labial veneers that require a high surface polish.

Hybrids have high compressive strength, tensile strength, and reasonable polishability. Inorganic filler materials vary widely between different composite systems. These materials are composed of the resin binding matrix and two different types of inorganic filler particles: microparticles ( $0.04 \mu\text{m}$ ) and macroparticles  $1 \mu\text{m}$  to  $15 \mu\text{m}$ . They are heavy-loaded inorganically (ie, 76% to 80% more by weight).<sup>12</sup> Hybrid composites are available in opaque and translucent shades. Translucent materials are ideal for the restoration of incisal



**Figure 5.** The hybrid composite is evenly placed over the entire facial surface. Incisal dentinal lobes are established and facial surface is contoured.



**Figure 6.** A brown or yellow tint is added to the cervical area to provide a more natural appearance. A translucent hybrid should also be added to the incisal region.

edges, and opaque hybrid composites have the ability to mask darkness in the underlying tooth structure. This opaque material effectively restores the dentin layer of the tooth. If the enamel layer is the only aspect that requires restoration, however, the hybrid layer may not be necessary. If no color change is required and the incisal edge remains intact, a microfill can be used alone with predictable and aesthetic results.

### **Microfill Composites**

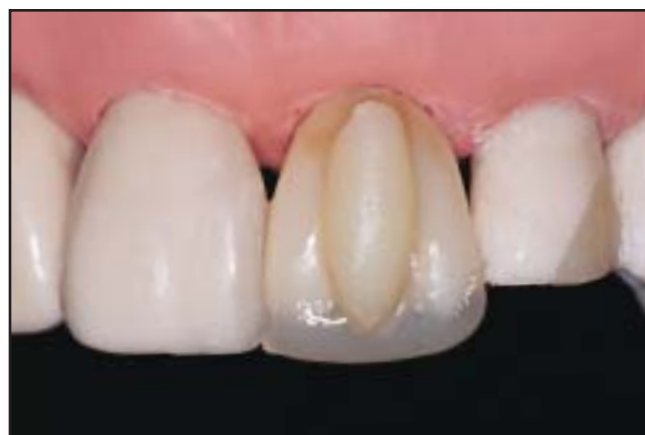The microfill composite is used as the surface layer for anterior restorations (ie, Micronew, Bisco, Schaumburg, IL; Matrixx, Discus Dental, Culver City, CA; Durafil, Heraeus Kulzer, Armonk, NY; Helimolar RO, Ivoclar Vivadent, Amherst, NY; Filtek A110, 3M ESPE, St. Paul, MN).

Microfills tend to be less highly filled, have smaller particle size, and are less fracture resistant. The inorganic filler of most microfilled composite systems is colloidal silica with a particle size of approximately  $0.04 \mu\text{m}$ . Microfill composites are generally loaded with inorganic filler materials at approximately 50% by weight.<sup>12</sup>

Microfills are also more translucent and polishable. Incisal shades of microfill resin should be selected if incisal translucency is required to replicate natural tooth structure. These resin formulations are indicated for anterior restorations that require a high polish (ie, Class III, Class V, small Class IV, and labial veneers); they should not be used for restorations that undergo heavy loading (ie, large Class IV composites, posterior restorations, core buildups).

### **Tints and Opaquers**

Tints and opaquers are used for intrinsic staining and characterization of the composite restoration (ie, Creative Color, Cosmedent, Chicago, IL; Kolor + Plus, Kerr/Sybron, Orange, CA; Tetric Color, Ivoclar Vivadent, Amherst, NY). Opaquers are highly pigmented, light-cured liquids that can be used to conceal dark tooth structure, translucency, and metal, and to change color. Incisal translucency is simulated using violet, gray, and blue tints. Slight gingival shade change can be accomplished with brown, orange, or honey-yellow tints. The use of tints and opaquers should be subtle, and these materials must always be overlaid with a microfill or hybrid resins. A complete composite restorative system



**Figure 7.** A cylinder of microfill composite is added to the facial surface. The placement of excess composite limits the creation of voids and pits in deficient areas.

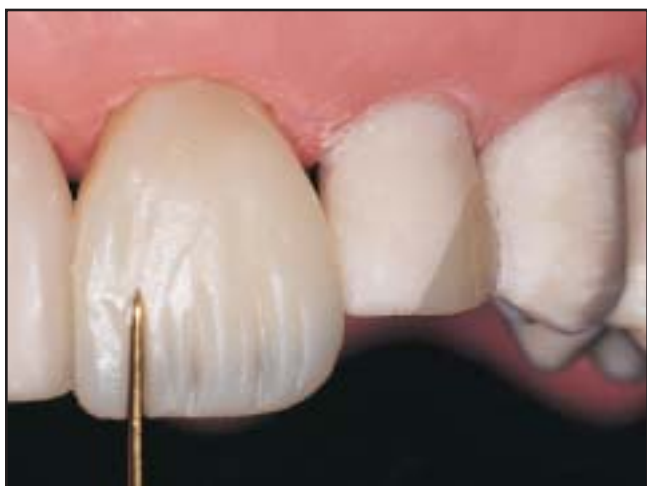should include an enamel replacement (translucent microfill shades that are highly polishable), dentin replacement (opaque hybrid shades), tints, and opaques.<sup>12</sup>

### Clinical Technique

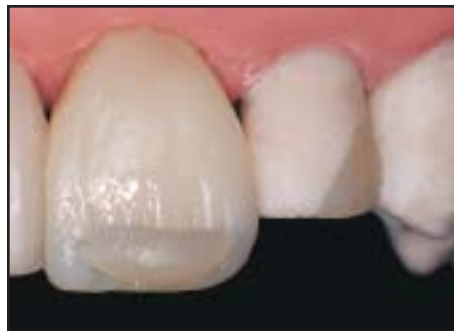In a clinical case, the first step is to determine the shade(s) of the teeth. A color map should be made to indicate the intended shade of the gingiva, middle, and incisal thirds. The clinician should then decide the amount of incisal translucency, opacities, stains, and additional optical features necessary to provide a natural, aesthetic result (Figure 1). A preliminary veneer preparation is advised if significant color change is anticipated. This enables the application of an opaque hybrid layer, opaques, and the overlying microfill layer. An advance mockup of the intended final contour may also be performed, and a silicone matrix may be fabricated to guide the establishment of the incisal contours.<sup>13</sup>

### Tooth Preparation

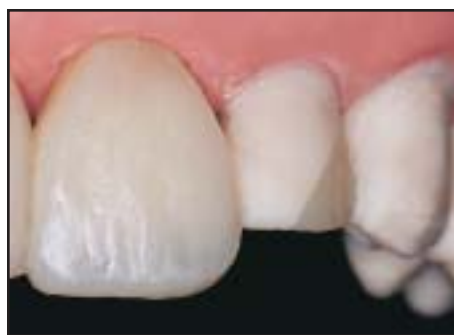For the purpose of this exercise, no attempt has been made to match the shade of the adjacent teeth in the typodont. A deep facial reduction (0.75 mm to 1 mm) should be performed to simulate deficient clinical teeth and enable subsequent restoration with the hybrid and microfill composite layering technique. The incisal edge can also be reduced by 1.5 mm to simulate a deficient incisal aspect and demonstrate the creation of proper translucency.



**Figure 8.** The incisal region should subsequently be intersculpted to characterize the tooth and provide a more natural effect.



**Figure 9.** It is necessary to “wet” the incisal area with unfilled resin or flowable incisal microfill during placement of the translucent incisal microfill composite.

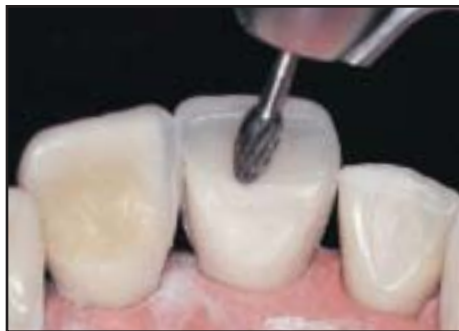

**Figure 10.** The final contour of tooth #9 is demonstrated prior to finishing.

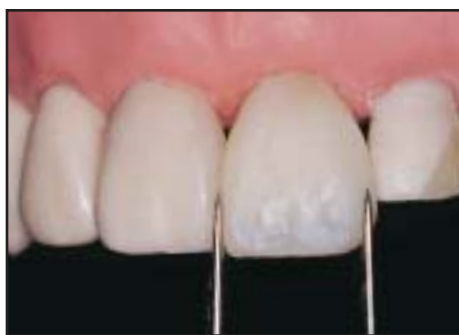Full veneer preparations are performed on teeth #9(12) through #11(23) to provide adequate space for the use of a hybrid (opaque dentin) and microfill (enamel/translucent) layer (Figure 2). For the purpose of the typodont exercise, a full 1-mm reduction was performed at the facial aspect, and 1.5 mm was removed from the incisal edge. The preparation should extend halfway into the contact area (Figure 3). While all veneer preparations do not require incisal reduction or as deep a facial reduction, this example is used to simulate a more complex situation and demonstrate the incisal effects of composite materials.

### Direct Resin Buildup

Restoring one tooth at a time allows the clinician to develop a more ideal interproximal contact area and overall shape and contour. The indicated tooth should be isolated using a matrix band or plastic strip and then be acid-etched; an adhesive agent should subsequently be applied. A cylinder of hybrid composite is then added



**Figure 11.** The lingual excess is trimmed with a high-speed football-shaped diamond bur.



**Figure 12.** The width of the veneer on tooth #9 should be compared to the width of tooth #8 using dividers or calipers.

to the tooth and evenly distributed (Figure 4). Care must be taken not to overcontour the interproximal areas. This hybrid layer is applied using a composite instrument, and dentinal lobes are established (Figure 5). The mamelon anatomy (incisal aspect of dentinal lobes) can be enhanced through the placement of ochre tint on tips of the lobes. The violet tint can be added to the lobe concavities and interproximal region to provide a more translucent effect prior to polymerization.

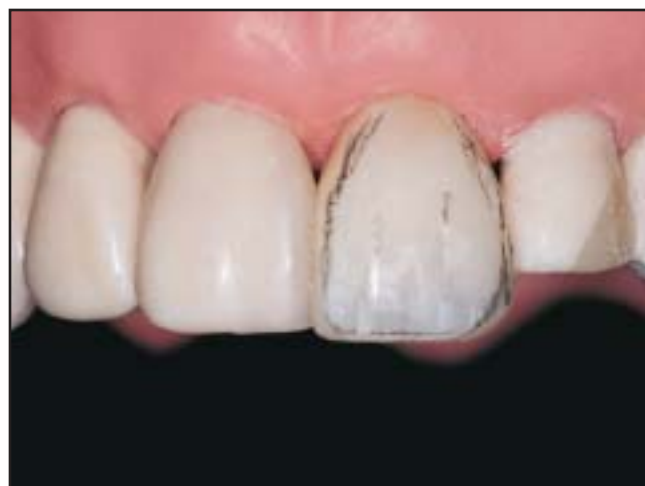Sufficient space should be left on the facial aspect for subsequent placement of the microfill layer following application of a translucent hybrid on the incisal region. The body and incisal regions of the hybrid layers are light cured for 20 seconds; a brown or yellow tint may be added to the cervical one third to provide a more natural appearance (Figure 6). A cylinder of body-shaded microfill resin can then be placed over the entire facial surface (Figure 7). The material should be placed in one increment and evenly spread out to avoid air entrapment that may result in white lines and pits on the final surface.

The composite material should be directly applied to the adjacent tooth without the use of a plastic strip. If the adjacent tooth is highly polished, the composite material should not adhere to this region, and a very tight and natural contact will be achieved. If the restorations are not highly polished interproximally, the composite material will stick together and result in chipping or a poor contact area. While a smooth surface is desirable, a thin plastic strip can be used to provide sufficient surface smoothness if a rough or unpolished surface exists. The body microfill must be thinned and sculpted at the incisal one third to provide space for the incisal layer (Figure 8). A thin coat of unfilled resin can subsequently be placed, and the translucent incisal microfill can then be added (Figure 9). Care should be taken to push the incisal microfill into the grooves to again avoid pits in the final restoration. While a flowable incisal microfill can also be used, bubbles in the material must be removed prior to polymerization.

Although the presence of excess material incisally and facially is acceptable, the interproximal contours must remain as close as possible to the final contours (Figure 10). The restoration must be completely light cured from all directions prior to contouring, finishing, and polishing.

### **Contouring**

A football-shaped carbide bur should first be used to contour the lingual aspect (Figure 11). A coarse finishing



**Figure 13.** The line angles and heights of contour can be drawn in pencil to match those of the adjacent tooth.



disc can be used to ensure that the incisal edge of #9 remains level with #8. The facial contours are subsequently created with a flame-tipped carbide bur and the coarse finishing disc, which can also facilitate even reduction of the composite surface. The tooth thickness and the position of the incisal edge are then established. The tooth should be viewed incisally to verify the accuracy of the three planes of facial contour. The width of tooth #9 should also be verified with a divider to ensure its congruency with tooth #8 (Figure 12).

### **Finishing**

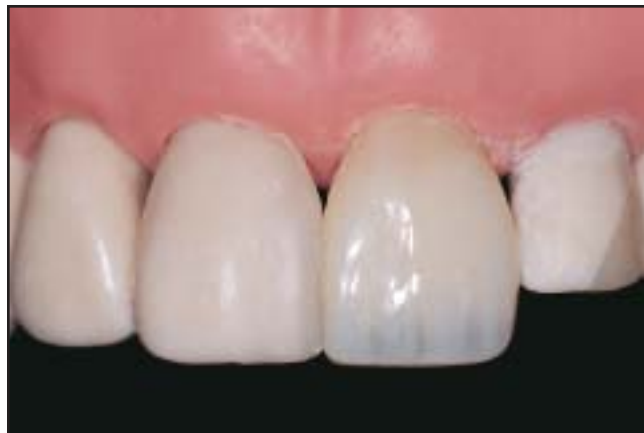Once the basic tooth shape is established, the line angles and heights of contour should be created. It is often helpful to actually draw these characterizations in pencil on the tooth (Figure 13). If present, the contralateral tooth may provide the necessary details and/or guidance. The incisal embrasures should be equivalent from right to left, and a successively larger incisal embrasure space from the central incisors that increases in size to the premolar region should be evident. The gingival embrasures should also be symmetrical. In order to maintain the contours during the polishing process, a smooth facial surface should be created prior to the establishment of facial dentinal lobes or developmental depressions.<sup>14</sup>

### **Polishing**

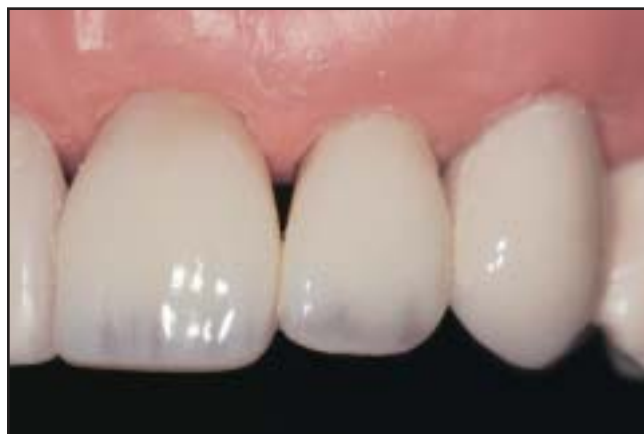The coarse polishing disc should be used to initiate the polishing sequence, followed by the medium, fine, extra-fine, and superfine polishing discs. A successive series of smaller and smaller scratches should be created until they finally disappear and leave a highly polished surface. Since use of polishing discs enables composite removal, they should be used to establish the initial contours.

The subtle surface characterizations should be evaluated, and a high polish should be established on the final surface layer. Horizontal perikymata can be placed using a coarse diamond bur with a “feather-touch” from the mesial to distal aspects. Irregularities in surface character can also be placed. The final surface polish and luster is placed with a flexible buff wheel and polishing paste (Flexibuff and Enamelize, Cosmedent, Chicago, IL), which spreads out over the tooth surface and evenly polishes the composite (Figure 14).

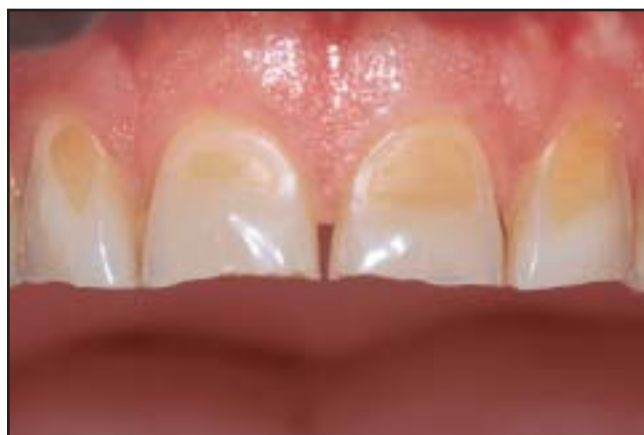Once this restoration is completed, the same process would be followed for the adjacent tooth. Note that if



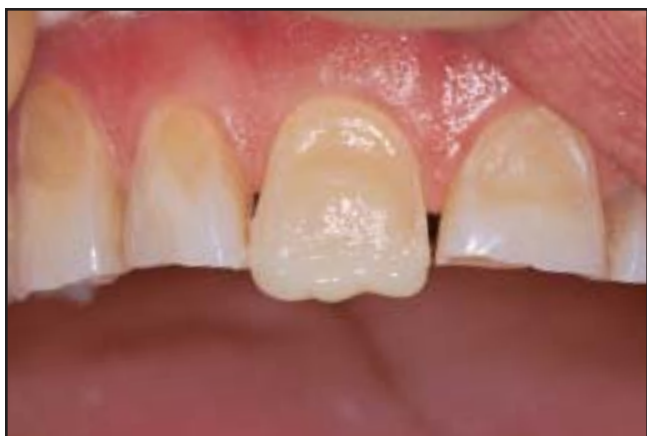**Figure 14. Facial view of the direct resin veneer after finishing and polishing.**



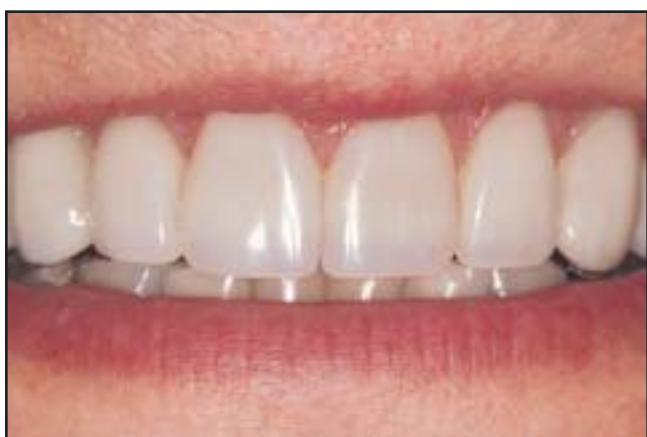**Figure 15. Postoperative view of the direct resin veneer restorations placed on the typodont model.**



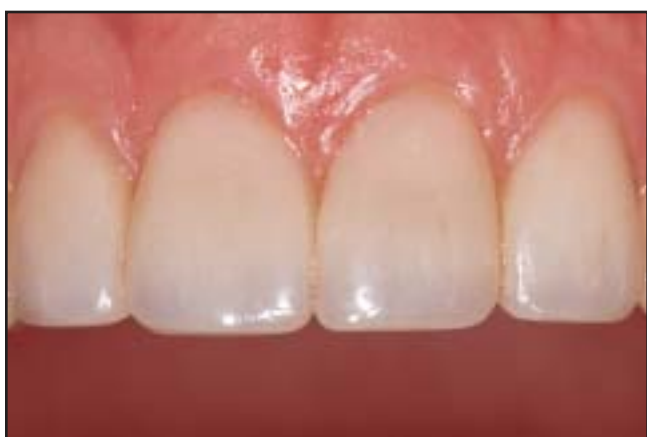**Figure 16. Preoperative facial view demonstrates the presence of extensive abrasion, erosion, and worn incisal edges.**



**Figure 17.** Once tooth #8 was etched and bonded, a hybrid composite was added to the facial aspect.



**Figure 18.** Upon completion of direct resin veneers for the six anterior dentition, teeth #4, #5, #12, and #13 were subsequently restored to fill the dark buccal corridors.



**Figure 19.** Postoperative facial view demonstrates the aesthetic integration of the definitive restorations.

there is a dark stained area, an opaquer is used to conceal the darker area until it matches the rest of the tooth. Once the subsequent restoration is finished and polished, the other teeth can be restored (Figure 15). Hybrid, microfill, tint, and incisal composites are placed so the layers would overlap to enable refined blending and gradation of colors and materials.

### Case Presentation

A 43-year-old male patient presented with extensive abrasion and erosion of the maxillary dentition (Figure 16). Direct composite resin restorations were selected to enable immediate modification of length and contour. A direct intraoral mockup was prepared to determine the incisal length and assess aesthetics, phonetics, and lip support.<sup>13</sup> Once patient approval was obtained, the length of the anterior teeth was determined, and the mockup was sectioned to guide the establishment of incisal length.

Teeth #6(13) through #11(23) were planned for direct bonding procedures, and the patient declined anesthetic treatment. The shade was determined with a color-corrected light. A diagnostic waxup was completed on mounted study models to facilitate determination of anterior guidance, clinical crown length, and the amount of bite opening required (approximately 4.5 mm). An intraoral mockup was fabricated to evaluate aesthetics and phonetics. Anterior guidance was established directly with composite resin and verified with articulating paper. Teeth #8 and #9 were prepared on the facial aspect with a technique similar to that used for porcelain veneer preparations. Since a significant color change was required, control over the tooth shade was very important. The central incisors were built up using the aforementioned technique, and centric stops were established on the lingual surface (Figure 17). A hybrid layer that included the dentinal lobes was added. Correct color, length, width, and contours of the central incisors had to be established prior to proceeding any further with the direct resin veneers.<sup>15</sup>

The lateral incisors and canines were subsequently built up, and the centric stops were established harmoniously with those of the central incisors. Excursive contacts were verified to provide canine guidance. The protrusive contacts were noted on the lingual surface of the central incisor and interferences were removed. The

anterior segment of the mandibular splint was removed as each tooth was restored. Use of the composite resin material enabled direct manipulation against the adjacent dentition for the best possible contour and contact, and the restorations were polished to establish balance. The maxillary premolars were restored at a subsequent visit to close the dark buccal corridor, and the mandibular splint was removed to allow each new restoration to function in harmony. The absence of any joint pain and no further occlusal wear indicated that proper guidance and function had been achieved. A dramatic aesthetic modification was evident upon completion and the patient was pleased with the definitive result (Figure 18).

### Occlusal Analysis

The first phase consisted of opening the bite with a full-time mandibular splint. The anterior segment was opened 3 mm to 4 mm in composite resin and canine guidance was established. The treatment plan for the posterior reconstruction included porcelain onlays and crowns on teeth #3(16) through #5(14), #12(24) through #14(26), #18(37) through #21(34), and #28(44) through #31(47). This treatment has not yet been commenced. A diagnostic waxup was completed, and temporary restorations (BioTemps, Glidewell Laboratories, Newport Beach, CA) have been fabricated. Fixed prosthodontic consultation was performed for proper occlusal analysis, to verify anterior guidance, and to review the overall treatment plan.

Upon reevaluation 4 years postoperatively, the direct resin veneers demonstrated strength against the forces of mastication, clenching, and staining (Figure 19). The patient wore through his original splint and the direct veneers have been in complete function for two years. A new nightguard was advised to protect against wear and potential fracture.

### Conclusion

This article demonstrates a clinical workshop technique for placing direct composite resins with a layering protocol that incorporates successive application of dentin, enamel, and incisal composite to achieve aesthetic restorations. Optimal clinical success can be accomplished once the clinician has an adequate understanding of preparation and composite layering techniques, the use of tints and opaques, and contouring

and polishing protocols. Direct resin restoration may be difficult and frustrating without practice. The principles of contouring and polishing are critical to the success of direct and indirect restorations, and this understanding will significantly improve laboratory/clinician communication.<sup>16</sup> The aforementioned exercise can also enable the clinician to fabricate improved direct veneer provisional restorations, particularly for the demanding patient. While this article described the direct layering process with composite hybrid and microfill materials, this concept can be applied to all systems, including contemporary microhybrid composites that contain opaque and dentin layers as well as a wide range of enamel shades.

### Acknowledgment

*The author mentions his gratitude to Dr. Bruce Crispin, Woodland Hills, CA, for his assistance in developing this presentation. The author declares no financial interest in any of the products cited herein.*

### References

1. Dietschi D. Freehand composite resin restorations: A key to anterior aesthetics. *Pract Periodont Aesthet Dent* 1995;7(7):15-25.
2. Baratieri LN. Aesthetics: Direct Adhesive Restoration on Fractured Anterior Teeth. Carol Stream, IL: Quintessence Publishing, 1998.
3. Fahl N Jr. Trans-surgical restoration of extensive Class IV defects in the anterior dentition. *Pract Periodont Aesthet Dent* 1997;9(7):709-720.
4. Bowen RL, Eichmiller FC, Marjenhoff WA. Gazing into the future of aesthetic restorative materials. *J Am Dent Assoc* 1992;123(5):32-39.
5. Fahl NJ Jr. Achieving ultimate anterior aesthetics with a new microhybrid composite. *Compend* 2000;21(suppl No. 26):4-13.
6. Vanini L. Light and color in anterior composite restorations. *Pract Periodont Aesthet Dent* 1996;8(7):673-682.
7. Fahl N Jr. The direct/indirect composite resin veneers: A case report. *Pract Periodont Aesthet Dent* 1996;8(7):627-638.
8. Nash RW. Freehand composite veneering — The direct option. *Pract Periodont Aesthet Dent* 1994;6(3):89-94.
9. Christensen GJ. Veneering of teeth. State of the art. *Dent Clin North Am* 1985;29(2):373-391.
10. Albers HF. Tooth-Colored Restoratives. Santa Rosa, CA: Alto Books; 1996:6a1-6a9.
11. Miller MB, ed. Reality. Volume 13. Houston, TX: Reality Publishing, 1999.
12. Jordan RE. Esthetic Composite Bonding: Techniques and Materials. St. Louis, MO: Mosby; 1993:163-173.
13. Behle C. Placement of direct composite veneers utilizing a silicone buildup guide and intraoral mock-up. *Pract Periodont Aesthet Dent* 2000;12(3):259-266.
14. Rufenacht C. Fundamentals of Aesthetics. Carol Stream, IL: Quintessence Publishing; 1990:137-145.
15. Spear F. The maxillary central incisal edge: A key to aesthetic and functional treatment planning. *Compend Contin Educ Dent* 1999;20(6):512-516.
16. Crispin, B.J. Contemporary Esthetic Dentistry: Practice Fundamentals. Carol Stream, IL: Quintessence Publishing; 1994:241-266.



# CONTINUING EDUCATION (CE) EXERCISE No. 8

To submit your CE Exercise answers, please use the answer sheet found within the CE Editorial Section of this issue and complete as follows: 1) Identify the article; 2) Place an X in the appropriate box for each question of each exercise; 3) Clip answer sheet from the page and mail it to the CE Department at Montage Media Corporation. For further instructions, please refer to the CE Editorial Section.

The 10 multiple-choice questions for this Continuing Education (CE) exercise are based on the article "Direct restoration of anterior teeth: Review of the clinical technique and case presentation" by James H. Peyton, DDS. This article is on Pages 203-210.

## Learning Objectives:

This article describes a laboratory workshop technique and clinical case for the placement of direct resin veneer restorations. Upon reading this article and completing this exercise, the reader should:

- Have an increased awareness of the layering technique for composite resins.
- Know the various applications for tints and opaquers.
- Understand how to obtain an enamel-like finish for composite restorations.

### 1. Polychromatic aesthetic direct resin veneers result from:

- a. Continual reduction of the incisal edge.
- b. Use of a hybrid resin for the surface layer.
- c. Placement of tints and opaquers on the surface layer.
- d. Use of a layering technique for hybrid and microfill composite materials.

### 2. Which of the following is a feature of microfill composite materials?

- a. Opaque quality.
- b. Highly polishable.
- c. Large particle size.
- d. High compressive strength.

### 3. Which of the following is a feature of hybrid composite materials?

- a. Highly polishable.
- b. Small particle size.
- c. Low compressive strength.
- d. Applicable for posterior restorations.

### 4. The purpose of an intraoral mockup is to determine all of the following EXCEPT:

- a. Phonetics.
- b. Lip support.
- c. Incisal length.
- d. Tooth preparation.

### 5. In the use of a typodont, it is important to:

- a. Create subgingival margins.
- b. Match the color of the plastic teeth.
- c. Follow the contours of the adjacent teeth.
- d. Use a plastic matrix strip throughout the entire procedure.

### 6. Why must the facial-incisal layer of body microfill be thinned?

- a. To increase the opacity.
- b. To provide a thin incisal edge.
- c. To provide room for the incisal microfill.
- d. To increase the strength of the restoration.

### 7. One reason to restore one tooth at a time would be to:

- a. Increase the length of the tooth.
- b. Create a more translucent restoration.
- c. Idealize the interproximal contact area.
- d. Minimize the use of the hybrid composite material.

### 8. In the composite layering process, dentinal lobes are created by:

- a. A strong dentinal bond.
- b. Contouring the hybrid composite.
- c. The use of a yellow-tinted opaquer.
- d. The application of rounded incisal edges.

### 9. Why must composite layers be added in one large piece at a time?

- a. To increase the bond strength.
- b. To distribute composite in an even thickness.
- c. To minimize expenditure for restorative materials.
- d. To increase the translucency of the restored tooth.

### 10. Why is a flexible polishing disc required during the finishing process?

- a. It does not scratch the surface of the tooth.
- b. The device avoids heat buildup during rapid reduction.
- c. The device is rigid and quickly cuts the composite material.
- d. The device spreads out over the tooth surface and evenly reduces the composite.