

Complex Odontogenic Infections

Larry J. Peterson



CHAPTER

CHAPTER OUTLINE

FASCIAL SPACE INFECTIONS

Maxillary Spaces

MANDIBULAR SPACES

Secondary Fascial Spaces

Cervical Fascial Spaces

Management of Fascial Space Infections

OSTEOMYELITIS

ACTINOMYCOSIS

CANDIDOSIS

Odontogenic infections are usually mild and easily treated by antibiotic administration and local surgical treatment. Abscess formation in the buccolingual vestibule is managed by simple intraoral incision and drainage (I&D) procedures, occasionally including dental extraction. (The principles of management of routine odontogenic infections are discussed in Chapter 15.) Some odontogenic infections are very serious and require management by clinicians who have extensive training and experience. Even after the advent of antibiotics and improved dental health, serious odontogenic infections still sometimes result in death. These deaths occur when the infection reaches areas distant from the alveolar process. The purpose of this chapter is to present overviews of fascial space infections of the head and neck caused by odontogenic infections and several of the more frequently seen unusual infections of the oral cavity.

FASCIAL SPACE INFECTIONS

The erosion process of infections through bone into surrounding soft tissue is discussed in Chapter 15. As a general rule infection erodes through the thinnest bone

and causes infection in the adjacent tissue. Whether or not this becomes a vestibular or fascial space abscess is determined primarily by the relationship of the muscle attachment to the point at which the infection perforates. Most odontogenic infections penetrate the bone in such a way that they become vestibular abscesses. On occasion they erode into fascial spaces directly, which causes a fascial space infection (Fig. 16-1). Fascial spaces are fascia-lined areas that can be eroded or distended by purulent exudate. These areas are potential spaces that do not exist in healthy people but become filled during infections. Some contain named neurovascular structures and are known as *compartments*; others, which are filled with loose areolar connective tissue, are known as *clefts*.

The spaces that are involved directly are known as the *fascial spaces of primary involvement*. The principal maxillary primary spaces are the canine, buccal, and infratemporal spaces (Box 16-1). The principal mandibular primary spaces are the submental, buccal, submandibular, and sublingual spaces. Infections can extend beyond these primary spaces into additional fascial spaces, or secondary spaces.

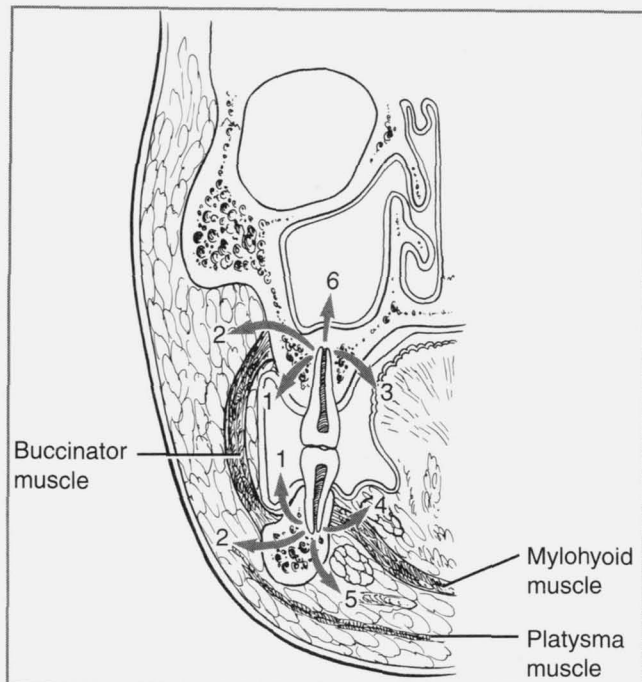


FIG. 16-1 As infection erodes through bone, it can express itself in a variety of places, depending on thickness of overlying bone and relationship of muscle attachments to site of perforation. This illustration notes six possible locations: vestibular abscess (1), buccal space (2), palatal abscess (3), sublingual space (4), submandibular space (5), and maxillary sinus (6). (From Cummings CW et al, editors: *Otolaryngology: head and neck surgery*, vol 3, St Louis, 1998, Mosby.)

BOX 16-1

Spaces Involved in Odontogenic Infections

Primary Maxillary Spaces

- Canine
- Buccal
- Infratemporal

Primary Mandibular Spaces

- Submental
- Buccal
- Submandibular
- Sublingual

Secondary Fascial Spaces

- Masseteric
- Pterygomandibular
- Superficial and deep temporal
- Lateral pharyngeal
- Retropharyngeal
- Prevertebral

Maxillary Spaces

The canine space is a thin potential space between the levator angulioris and the levator labii superioris muscles. The canine space becomes involved primarily as the result of infections from the maxillary canine tooth.

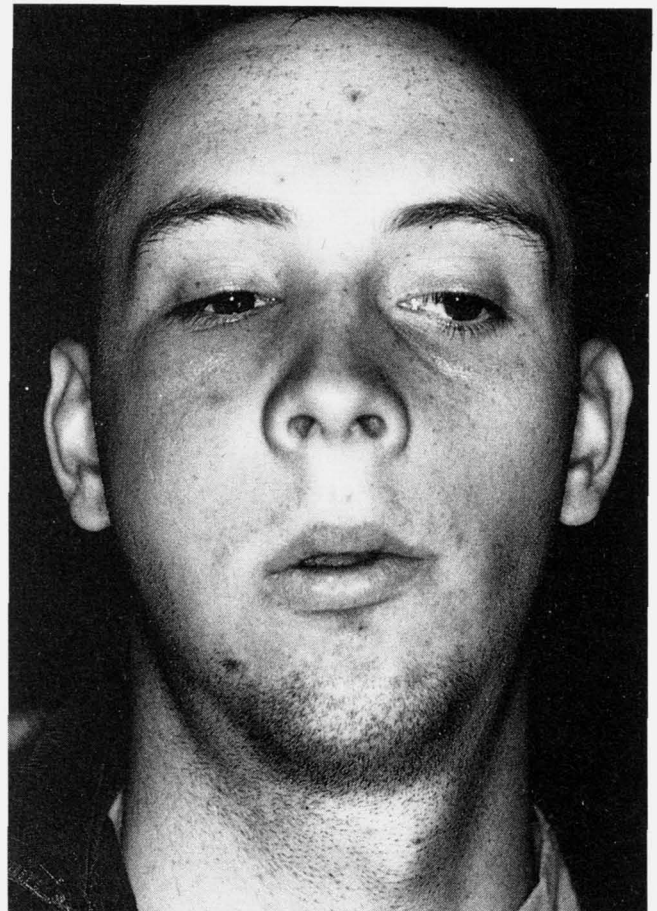


FIG. 16-2 Canine space infection in patient's right side resulted from infected canine tooth. The swelling of nasolabial and infraorbital areas is demonstrated.

This is the only tooth with a root sufficiently long to allow erosion to occur through the alveolar bone superior to the muscles of facial expression. The infection erodes superior to the origin of the levator anguli oris muscle and below the origin of the levator labii superioris muscle. When this space is infected, swelling of the anterior face obliterates the nasolabial fold (Fig. 16-2). Spontaneous drainage of infections of this space commonly occurs just inferior to the medial canthus of the eye.

The buccal space is bounded by the overlying skin of the face on the lateral aspect and the buccinator muscle on the medial aspect (Fig. 16-3). This space may become infected from extensions of infection from either the maxillary or mandibular teeth. The posterior maxillary teeth, most commonly the molars, cause most buccal space infections. The buccal space becomes involved from the teeth when infection erodes through the bone superior to the attachment of the buccinator muscle.

Involvement of the buccal space usually results in swelling below the zygomatic arch and above the inferior border of the mandible. Thus both the zygomatic arch and the inferior border of the mandible are palpable in buccal space infections.

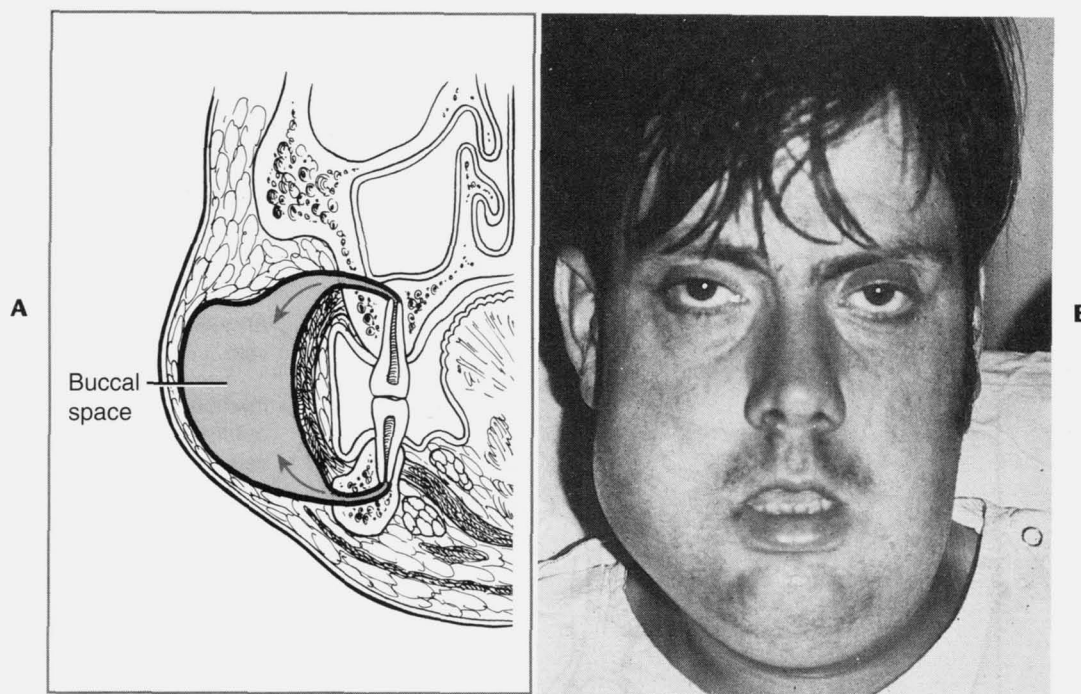


FIG. 16-3 A, Buccal space lies between buccinator muscle and overlying skin and superficial fascia. This potential space may become involved via maxillary or mandibular molars (arrows). B, This buccal space infection was result of maxillary molar. Typical swelling of the cheek is demonstrated, which does not extend beyond inferior border of mandible. (From Cummings CW et al, editors: Otolaryngology: head and neck surgery, vol 3, St Louis, 1998, Mosby.)

The infratemporal space lies posterior to the maxilla. It is bounded medially by the lateral plate of the pterygoid process of the sphenoid bone and superiorly by the base of the skull. Laterally, the infratemporal space is continuous with the deep temporal space. The infratemporal space is rarely infected, but when it is, the cause is usually an infection of the maxillary third molar (Fig. 16-4).

Maxillary odontogenic infections may also spread superiorly to cause secondary periorbital or orbital cellulitis or cavernous sinus thrombosis. Periorbital or orbital cellulitis rarely occurs as the result of odontogenic infection, but when either does occur, the presentation is typical: redness and swelling of the eyelids and involvement of both the vascular and neural components of the orbit. This is a serious infection and requires aggressive medical and surgical intervention from multiple specialists.

Cavernous sinus thrombosis may also occur as the result of superior spread of odontogenic infection via a hematogenous route (Fig. 16-5). Bacteria may travel from the maxilla posteriorly via the pterygoid plexus and emissary veins or anteriorly via the angular vein and inferior or superior ophthalmic veins to the cavernous sinus. The veins of the face and orbit lack valves, which permits blood to flow in either direction. Thus bacteria can travel via the venous drainage system and contaminate the cavernous sinus, which results in thrombosis. Cavernous sinus thrombosis is an unusual occurrence that is rarely the result of an infected tooth. Like orbital cellulitis, cavernous sinus thrombosis is a serious, life-threatening infection that requires aggressive medical and surgical care. Cavernous sinus thrombosis has a high mortality even today.

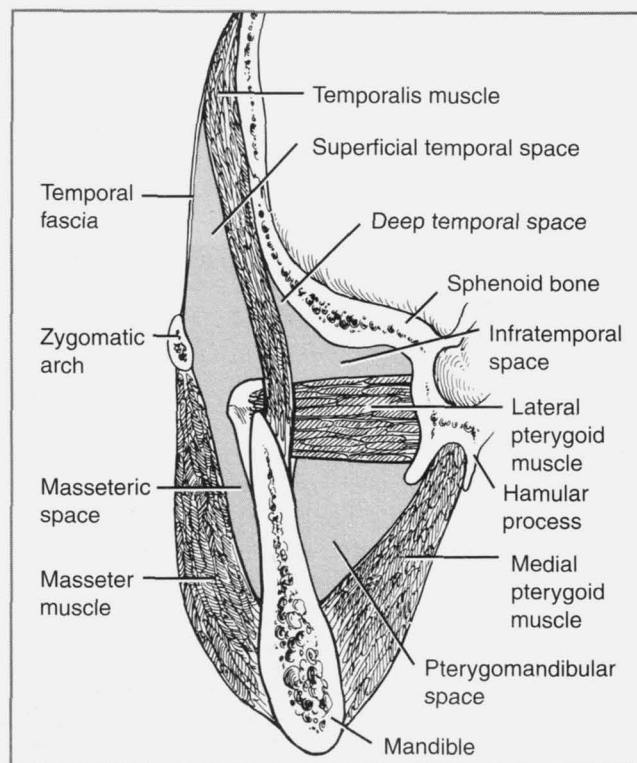


FIG. 16-4 Spaces of ramus of mandible are bounded by masseter muscle, medial pterygoid muscle, temporal fascia, and skull. Temporal space is divided into deep and superficial portions and by temporalis muscle. (Redrawn from Cummings CW et al, editors: Otolaryngology: head and neck surgery, vol 3, St Louis, 1998, Mosby.)

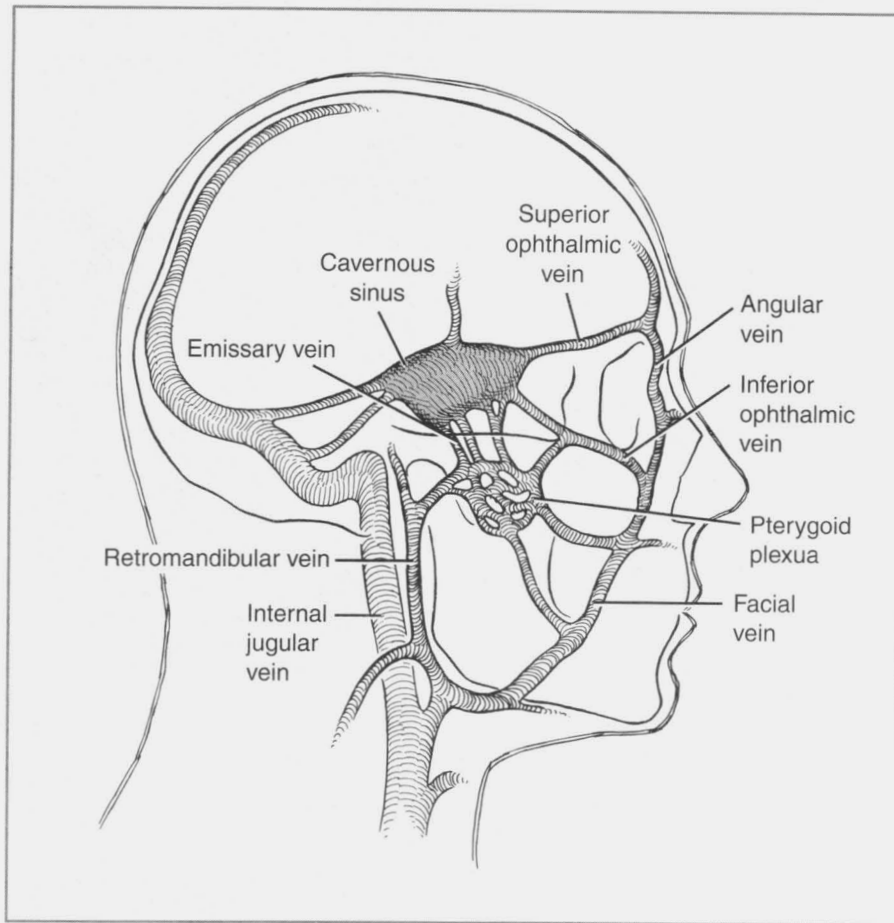


FIG. 16-5 Hematogenous spread of infection from jaw to cavernous sinus may occur anteriorly via inferior or superior ophthalmic vein or posteriorly via emissary veins from pterygoid plexua. (From Cummings CW et al, editors: *Otolaryngology: head and neck surgery*, vol 3, St Louis, 1998, Mosby.)

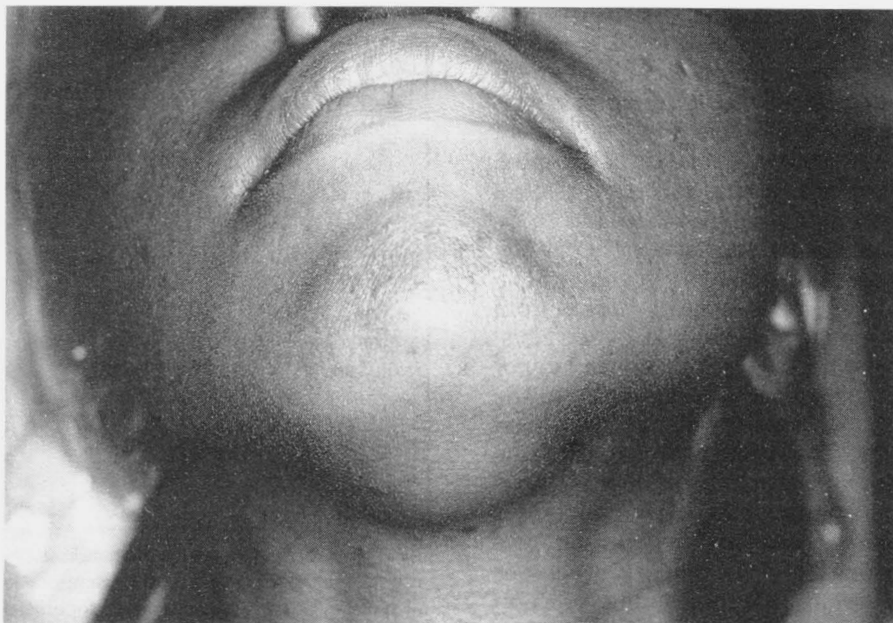


FIG. 16-6 Submental space infection appears as discrete swelling in central area of submandibular region.

MANDIBULAR SPACES

Although most infections of the mandibular teeth erode into the buccal vestibule, they may also spread into fascial spaces. The four primary mandibular spaces are (1) the submental, (2) the buccal, (3) the sublingual, and (4) the submandibular spaces.

The submental space lies between the anterior bellies of the digastric muscle and between the mylohyoid muscle and the overlying skin (Fig. 16-6). This space is primarily infected by mandibular incisors, which are sufficiently long to allow the infection to erode through the labial bone apical to the attachment of the mentalis muscle. The infection is thus allowed to proceed under the inferior border of the mandible and involve the submental space. Isolated submental space infection is a rare occurrence.

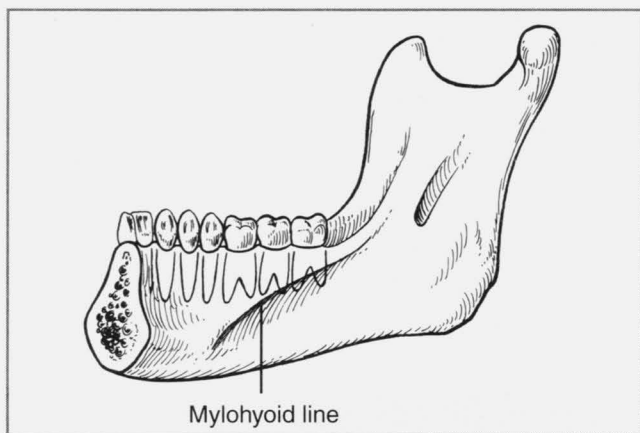


FIG. 16-7 Mylohyoid line is area of attachment of mylohyoid muscle. Linguocortical plate perforation by infection from premolars and first molar causes sublingual space infection, whereas infection from third molar involves submandibular space. (From Cummings CW et al, editors: *Otolaryngology: head and neck surgery*, vol 3, St Louis, 1998, Mosby.)

The buccal space can be infected as an extension of infection from mandibular teeth, similar to the way in which it is involved from the maxillary teeth (see Fig. 16-3). The buccal space is most commonly infected from maxillary teeth but can also be involved from the mandibular teeth.

The sublingual and submandibular spaces have the medial border of the mandible as their lateral boundary. These two spaces are involved primarily by lingual perforation of infection from the mandibular molars, although they may be involved by premolars, as well. The factor that determines whether the infection is submandibular or sublingual is the attachment of the mylohyoid muscle on the mylohyoid ridge of the medial aspect of the mandible (Fig. 16-7). If the infection erodes through the medial aspect of the mandible above this line, the infection will be in the sublingual space and is most commonly seen with premolars and the first molar. If the infection erodes through the medial aspect of the mandible inferior to the mylohyoid line, the submandibular space will be involved. The mandibular third molar is the tooth that most commonly involves the submandibular space primarily. The second molar may involve either the sublingual or submandibular space, depending on the length of the individual roots, and may involve both spaces primarily.

The sublingual space lies between the oral mucosa of the floor of the mouth and the mylohyoid muscle (Fig. 16-8, A). Its posterior border is open, and therefore it freely communicates with the submandibular space and the secondary spaces of the mandible to the posterior aspect. Clinically little or no extraoral swelling is produced by an infection of the sublingual space, but much intraoral swelling is seen in the floor of the mouth on the infected side (Fig. 16-8, B). The infection usually becomes bilateral, and the tongue becomes elevated.

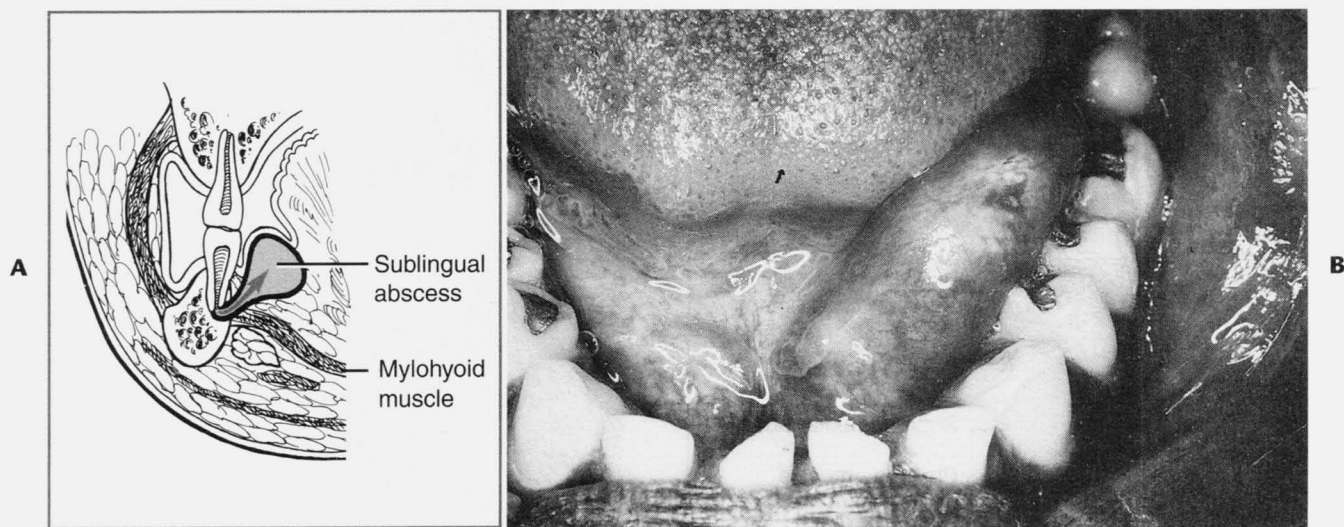


FIG. 16-8 A, Sublingual space between oral mucosa and mylohyoid muscle. It is primarily involved by infection from mandibular premolars and first molar. B, This isolated sublingual space infection produced unilateral swelling of floor of mouth. (From Cummings CW et al, editors: *Otolaryngology: head and neck surgery*, vol 3, St Louis, 1998, Mosby.)

The submandibular space lies between the mylohyoid muscle and the overlying skin and superficial fascia (Fig. 16-9). The posterior boundary of the submandibular space communicates with the secondary spaces of the jaw posteriorly. Infection of the submandibular space causes swelling that begins at the inferior border of the mandible and extends medially to the digastric muscle and posteriorly to the hyoid bone (Fig. 16-10).

When bilateral submandibular, sublingual, and submental spaces become involved with an infection, it is known as *Ludwig's angina*. This infection is a rapidly spreading cellulitis that commonly spreads posteriorly to the secondary spaces of the mandible.

Severe swelling is almost always seen, with elevation and displacement of the tongue, and a tense, hard induration of the submandibular region superior to the hyoid bone.

The patient usually has trismus, drooling of saliva, and difficulty with swallowing and sometimes breathing. The patient often experiences severe anxiety concerning the inability to swallow and maintain an airway. This infection may progress with alarming speed and thus may produce upper airway obstruction that often leads to death. The most common cause of Ludwig's angina is an odontogenic infection, usually as the result of streptococci. This infection must be aggressively managed with vigorous I&D procedures and aggressive antibiotic therapy. Special attention must be given to maintenance of the airway.

Secondary Fascial Spaces

The primary spaces discussed so far are immediately adjacent to the tooth-bearing portions of the maxilla and mandible. If proper treatment is not received for infections of the primary spaces, the infections may extend posteriorly to involve the secondary fascial spaces. When these spaces are involved, the infections frequently

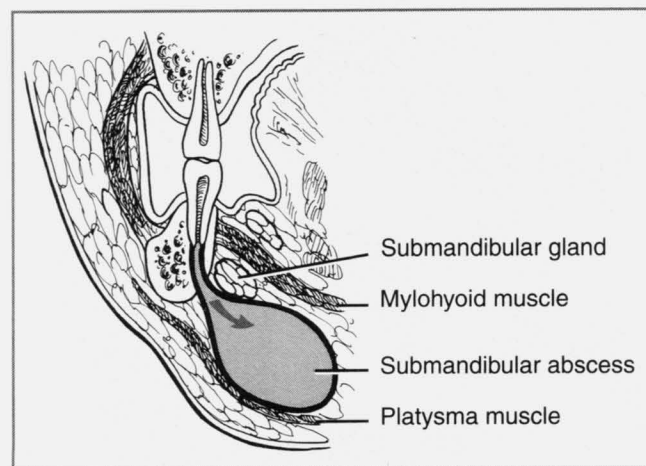


FIG. 16-9 Submandibular space lies between mylohyoid muscle and skin and superficial fascia. Primarily second and third molars infect it. (From Cummings CW et al, editors: *Otolaryngology: head and neck surgery*, vol 3, St Louis, 1998, Mosby.)

become more severe, cause greater complications and greater morbidity, and are more difficult to treat. Because a connective tissue fascia that has a poor blood supply surrounds these spaces, infections involving these spaces are difficult to treat without surgical intervention to drain the purulent exudate.

The masseteric space exists between the lateral aspect of the mandible and the medial boundary of the masseter muscle (see Fig. 16-4). It is involved by infection most commonly as the result of spread from the buccal space or from soft tissue infection around the mandibular third molar. When the masseteric space is involved, the area overlying the angle of the jaw and ramus becomes swollen. Because of the involvement of the masseter muscle, the patient will also have moderate-to-severe trismus caused by inflammation of the masseter muscle.

The pterygomandibular space lies medial to the mandible and lateral to the medial pterygoid muscle (see Fig. 16-4). This is the space into which local anesthetic solution is injected when an inferior alveolar nerve block is performed. Infections of this space spread primarily from the sublingual and submandibular spaces. When the pterygomandibular space alone is involved, little or no facial swelling is observed; however, the patient almost always has significant trismus. Therefore trismus without swelling is a valuable diagnostic clue for pterygomandibular space infection. The most common occur-

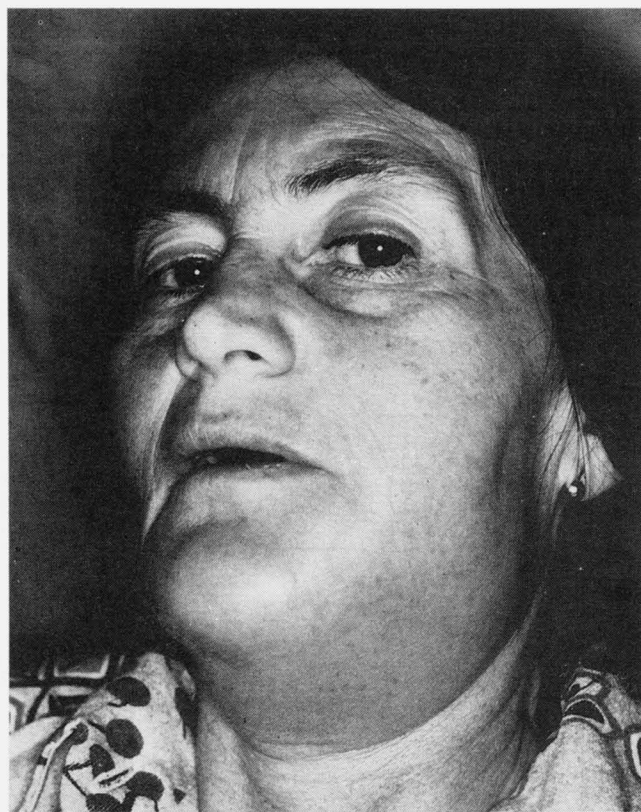

FIG. 16-10 This submandibular space infection produced large, indurated swelling of submandibular space. (From Cummings CW et al, editors: *Otolaryngology: head and neck surgery*, vol 3, St Louis, 1998, Mosby.)

rence of this clinical picture is caused by needle tract infection from a mandibular block.

The temporal space is posterior and superior to the masseteric and pterygomandibular spaces (see Fig. 16-4). It is divided into two portions by the temporalis muscle: (1) a superficial portion that extends to the temporal fascia and (2) a deep portion that is continuous with the infratemporal space. Rarely are the superficial and deep temporal spaces secondarily involved and usually only in severe infections. When these spaces are involved, the swelling that occurs is evident in the temporal area, superior to the zygomatic arch and posterior to the lateral orbital rim.

When taken as a group, the masseteric, pterygomandibular, and temporal spaces are known as the *masticator space*, because the muscles and fascia of mastication bound them. These spaces communicate freely with one another, so when one becomes involved the others may also. The term *masticator space* does have some general clinical usefulness, but it lacks specificity and is therefore less useful than specific space designations.

Cervical Fascial Spaces

Extension of odontogenic infections beyond the primary and secondary mandibular spaces is an uncommon occurrence. However, when it does happen, spread to deep cervical spaces may have serious life-threatening sequelae. These sequelae may be the result of locally induced complications, such as upper airway obstructions, or of distant problems, such as mediastinitis.

Infection extending posteriorly from the pterygomandibular space first encounters the lateral pharyngeal

space. This space extends from the base of the skull at the sphenoid bone to the hyoid bone inferiorly. It is medial to the medial pterygoid muscle and lateral to the superior pharyngeal constrictor on the medial side (Fig. 16-11). It is bounded anteriorly by the pterygomandibular raphe and extends posteromedially to the prevertebral fascia. The styloid process and associated muscles and fascia divide the lateral pharyngeal space into an anterior compartment, which contains primarily muscles, and a posterior compartment, which contains the carotid sheath and several cranial nerves.

The clinical findings of lateral pharyngeal space infection include severe trismus as the result of involvement of the medial pterygoid muscle; lateral swelling of the neck, especially inferior to the angle of the mandible; and swelling of the lateral pharyngeal wall, toward the midline. Patients who have lateral pharyngeal space infections have difficulty swallowing and usually have a high temperature and become quite sick.

Patients who have infection of the lateral pharyngeal space have several serious potential problems. When the lateral pharyngeal space is involved, the odontogenic infection is severe and may be progressing at a rapid rate. Another possible problem is the direct effect of the infection on the contents of the space, especially those of the posterior compartment. These problems include thrombosis of the internal jugular vein, erosion of the carotid artery or its branches, and interference with cranial nerves IX through XII. A third serious complication arises if the infection progresses from the lateral pharyngeal space to the retropharyngeal space.

The retropharyngeal space lies behind the soft tissue of the posterior aspect of the pharynx. It is bounded anteriorly

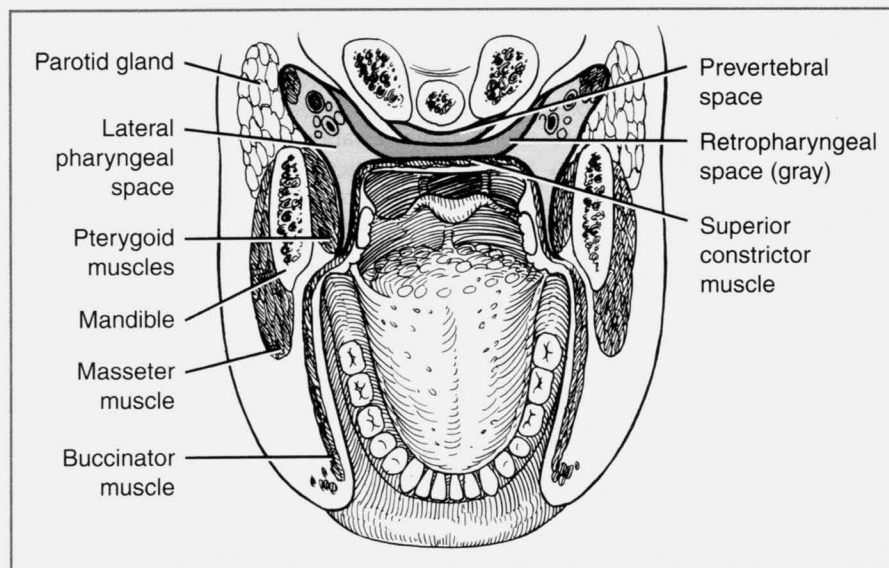


FIG. 16-11 Lateral pharyngeal space is located between medial pterygoid muscle on lateral aspect and superior pharyngeal constrictor on medial aspect. Retropharyngeal and prevertebral spaces lie between pharynx and vertebral column. Retropharyngeal space lies between superior constrictor muscle and alar portion of prevertebral fascia. Prevertebral spaces lie between alar layer and prevertebral fascia. (From Cummings CW et al, editors: *Otolaryngology: head and neck surgery*, vol 3, St Louis, 1998, Mosby.)

only by the superior pharyngeal constrictor muscle and its investing fascia and posteriorly by the alar layer of prevertebral fascia (see Fig. 16-11).

The retropharyngeal space begins at the base of the skull and extends inferiorly to the level of vertebra C7 or T1, where the alar fascia fuses anteriorly with the buccopharyngeal fascia (Fig. 16-12). The retropharyngeal space has few contents, and therefore infection in this space does not carry some of the grave problems that involvement of the lateral pharyngeal space does. However, when the retropharyngeal space becomes involved, the major concern is that the infection can extend inferiorly to the posterosuperior mediastinum relatively rapidly. Should infection spread by this route, the result may be extension of the infection into the mediastinum, which is a serious complication.

When a patient has extension of infection into the cervical region, the retropharyngeal space must be evaluated with lateral radiographs of the neck to determine if the space is enlarged and thereby compromising the airway (Fig. 16-13).

A final danger of retropharyngeal space infection is progressive involvement of the prevertebral space. The prevertebral space is separated from the retropharyngeal space by the alar layer of prevertebral fascia. If this fascia is perforated, the prevertebral space can become involved. The prevertebral space extends from the pharyngeal tubercle on the base of the skull to the diaphragm. Infection of this space can extend rapidly inferior to the level of the diaphragm (see Fig. 16-12) and can involve the thorax and mediastinum along the way.

When the retropharyngeal or prevertebral fascial spaces (or both) are involved as a result of odontogenic infection, the patient is almost always seriously ill. The following are the three greatest potential complications: (1) the serious possibility of upper-airway obstruction as a result of anterior displacement of the posterior pharyngeal wall into the oral pharynx; (2) rupture of the retropharyngeal space abscess, with aspiration of pus into the lungs and subsequent asphyxiation; and (3) spread of the infection from the retropharyngeal spaces into the mediastinum, which results in severe infection in the thorax.

Management of Fascial Space Infections

Management of infections, mild or severe, always has five general goals: (1) medical support of the patient, with special attention to correcting host defense compromises where they exist; (2) administration of proper antibiotics in appropriate doses; (3) surgical removal of the source of infection as early as possible; (4) surgical drainage of the infection, with placement of proper drains; and (5) constant reevaluation of the resolution of the infection. The principles of surgical and medical management of fascial space infections are the same as those for less serious infections. However, fascial space infections require more extensive and aggressive treatment.

Medical management of the patient with a serious infection must include a thorough assessment and support of host defense mechanisms, including analgesics,

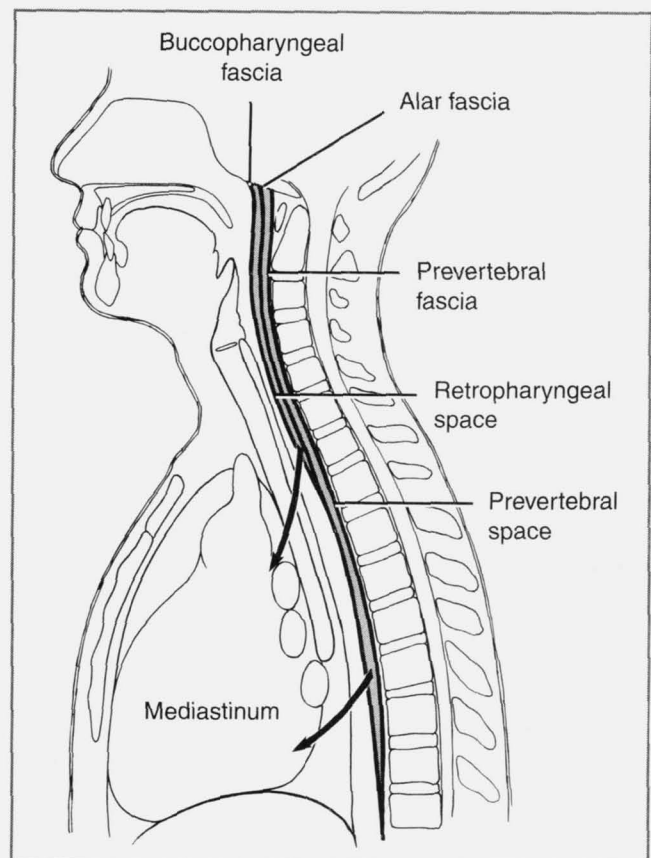


FIG. 16-12 If retropharyngeal space is involved, posterosuperior mediastinum may also become infected secondarily. If prevertebral space is infected, inferior boundary is diaphragm, so entire mediastinum is at risk. (From Cummings CW et al, editors: *Otolaryngology: head and neck surgery*, vol 3, St Louis, 1998, Mosby.)

fluid requirements, and nutrition. High-dose bactericidal antibiotics are usually necessary and are almost always administered intravenously. Additionally the patient's airway must be continually monitored, and a surgical airway established if warranted.

Surgical management of fascial space infections almost always requires a generous incision and aggressive exploration of the involved fascial spaces with a hemostat. One or more drains are usually required to provide adequate drainage and decompression of the infected area. Because I&D must be extensive, they are usually done in an operating room, with the patient under general anesthesia. The locations of various I&D sites are depicted in Fig. 16-14. Ample clinical experience and experimental evidence indicate that, although no pus formation can be detected by palpation or even by needle aspiration, even the serious cellulitis will resolve more rapidly if incised. The surgeon must not wait for unequivocal evidence of pus formation. In the preantibiotic era, surgical treatment was the only method of therapy for infections, and early and aggressive surgical therapy was frequently curative for these severe infections. It is important to remember that aggressive surgical exploration is still the primary method of therapy for serious odontogenic infections of the head and neck.

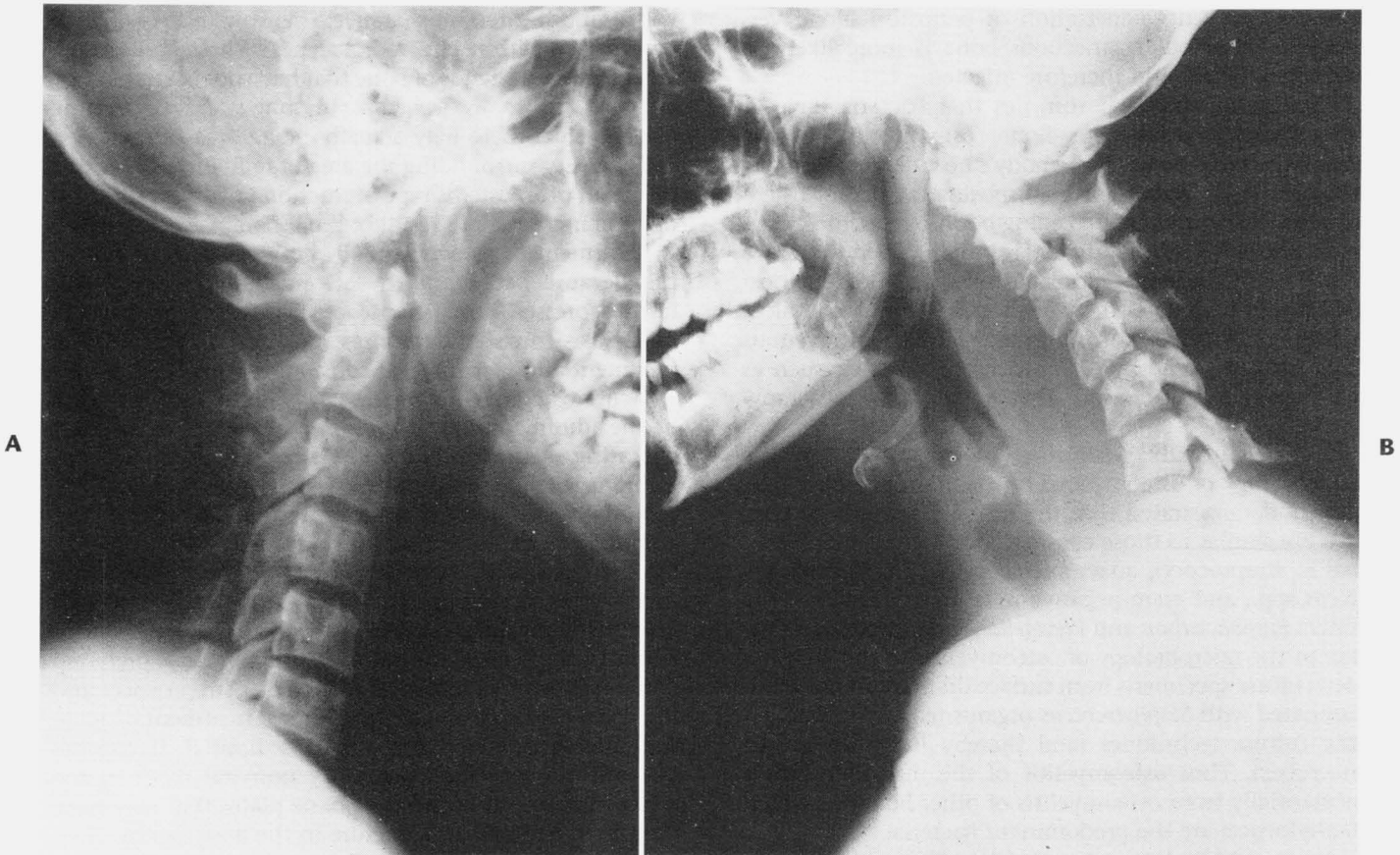


FIG. 16-13 A, Retropharyngeal soft tissue shadow is narrow (3 to 4 mm) and located at C2 and at C6. Retrotracheal soft tissue is usually 14 to 15 mm. B, When retropharyngeal space is involved, soft tissue becomes substantially thicker, and width of oropharyngeal air shadow decreases. (From Cummings CW et al, editors: Otolaryngology: head and neck surgery, vol 3, St Louis, 1998, Mosby.)

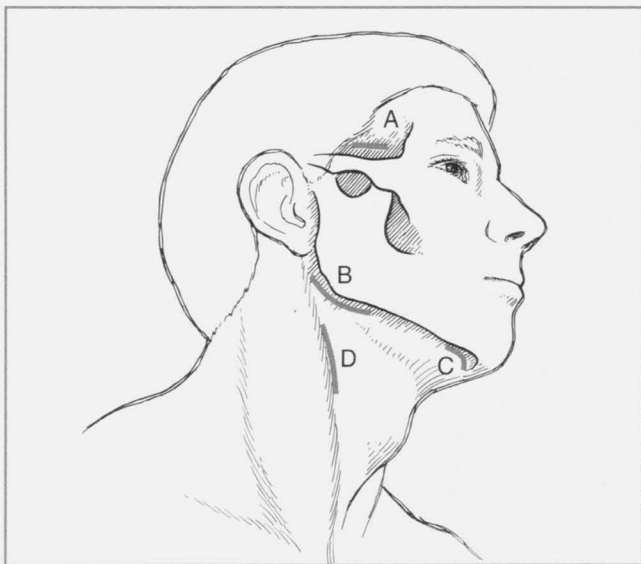


FIG. 16-14 Typical incision and drainage (I&D) sites for various fascial space infections. A, Superficial and deep temporal space (A). Submandibular masseteric and pterygomandibular spaces (B). Submental space (C). Lateral pharyngeal and retropharyngeal spaces (D). (From Cummings CW et al, editors: Otolaryngology: head and neck surgery, vol 3, St Louis, 1998, Mosby.)

OSTEOMYELITIS

The term *osteomyelitis* literally means inflammation of the bone marrow. Clinically, osteomyelitis usually implies an infection of the bone. It usually begins in the medullary cavity, involving the cancellous bone; then it extends and spreads to the cortical bone and eventually to the periosteum. Invasion of bacteria into the cancellous bone, which causes inflammation and edema in the marrow spaces, results in compression of the blood vessels in the bone and subsequent severe compromise of the blood supply. The failure of microcirculation in the cancellous bone is a critical factor in the establishment of osteomyelitis, because the involved area becomes ischemic and bone becomes necrotic. Bacteria can then proliferate, because normal blood-borne defenses do not reach the tissue, and the osteomyelitis spreads until it is stopped by medical and surgical therapy.

Although the maxilla can also become involved in osteomyelitis, it does so rarely compared with the mandible. The primary reason for this is that the blood supply to the maxilla is much richer and is derived from several arteries, which form a complex network of feeder vessels. Because the mandible tends to draw its primary blood supply from the inferior alveolar artery, and because the dense overlying cortical bone of the

mandible prevents penetration of periosteal blood vessels, the mandibular cancellous bone is more likely to become ischemic and therefore infected.

Considering the opportunities that bacteria have to enter into the cancellous bone, osteomyelitis of the mandible rarely occurs if the body's host defenses are reasonably intact. The major predisposing factors for osteomyelitis of the jaws are preceding odontogenic infections and fractures of the mandible (Fig. 16-15). Even these two events rarely cause infections of the bone unless the host defenses are suppressed by problems such as the alcoholism malnutritional syndrome, diabetes, intravenous illicit drug use, and myeloproliferative diseases, such as the leukemias, sickle cell disease, and chemotherapy-treated cancer.

Recent carefully performed investigations on the microbiology of osteomyelitis of the mandible have adequately demonstrated that the primary bacteria of concern are similar to those causing odontogenic infections, that is, streptococci, anaerobic cocci such as *Peptostreptococcus* spp., and gram-negative rods such as those of the genera *Fusobacterium* and *Prevotella*. Traditional investigation of the microbiology of osteomyelitis of the jaws has used culture specimens from surface drainage of pus (contaminated with *Staphylococcus* organisms) and not anaerobic culture techniques (and thereby have not grown anaerobes). Thus osteomyelitis of the mandible differs substantially from osteomyelitis of other bones in which staphylococci are the predominant bacteria.

Acute suppurative osteomyelitis shows little or no radiographic change, because 10 to 12 days are required for lost bone to be detectable radiographically. Chronic osteomyelitis usually demonstrates bony destruction in the area of infection. The appearance is one of increased radiolucency, which may be uniform in its pattern or patchy,

with a "moth-eaten" appearance. There may also be areas of radiopacity within the radiolucency. These radiopaque areas represent islands of bone that have not been resorbed and are known as *sequestra*. In long-standing chronic osteomyelitis there may actually be an area of increased radiodensity surrounding the area of radiolucency. This is the result of an osteitis type of reaction in which bone production increases as a result of the inflammatory reaction.

Treatment of osteomyelitis is both medical and surgical. Because patients with osteomyelitis almost always have depressed host defense mechanisms, the clinician must take these compromises into account during the treatment and seek medical consultation when necessary.

Acute osteomyelitis of the jaws is primarily managed by the administration of appropriate antibiotics. The precipitating event, condition, or both must also be carefully managed. If the event is a fracture of the mandible, careful attention must be given to its treatment. The antibiotic of choice is clindamycin, because it is effective against streptococci and the anaerobes that are usually involved in osteomyelitis. If the patient has a serious acute osteomyelitis, hospitalization may be required for administration of IV antibiotics. Clindamycin is preferred because it is an excellent drug for both streptococci and the usual causative anaerobes. Surgical treatment of acute suppurative osteomyelitis is usually limited. It consists primarily of removing obviously nonvital teeth in the area of the infection, wires or bone plates that may have been used to stabilize a fracture in the area, or any obviously loose pieces of bone. For acute osteomyelitis that results from jaw fracture, the surgeon must stabilize the mobile segments of the mandible with tight intermaxillary fixation or some other technique.

Chronic osteomyelitis requires not only aggressive antibiotic therapy but also aggressive surgical therapy.

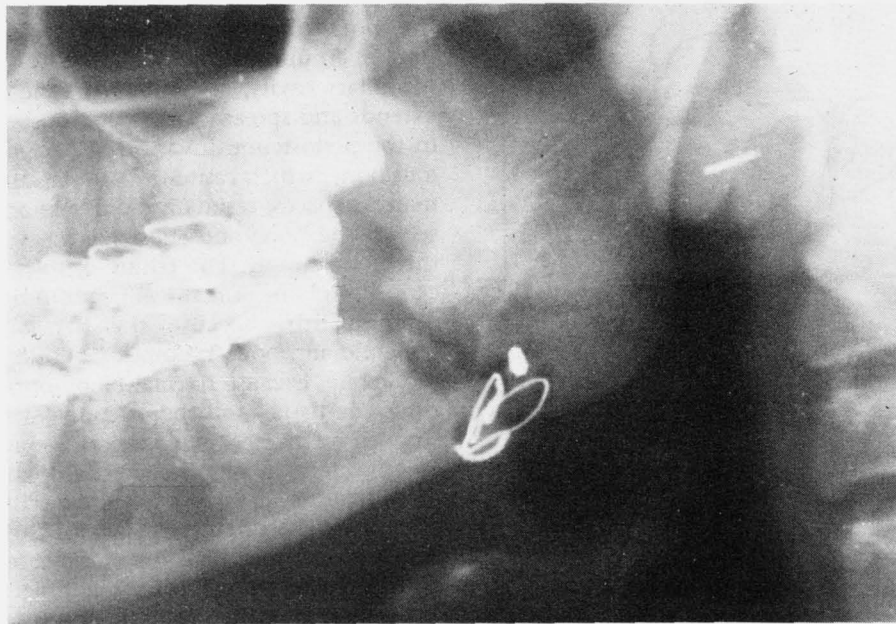


FIG. 16-15 Osteomyelitis occurred in the area of a fracture of the mandible of a patient who was poorly nourished and abused ethanol. The sequestra is surrounded by the radiolucency.

Because of the severe compromise in the blood supply to the area of osteomyelitis, the patient is usually admitted to the hospital and given high-dose IV antibiotics to control the initial symptoms. Clindamycin is the drug of choice. An effort should be made to obtain culture material at the time of surgery so that the selection of an antibiotic can be based on the specific microbiology of the infection.

Therapy for both acute and chronic osteomyelitis, most authorities agree, should ensure that antibiotics are continued for a much longer time than is usual for odontogenic infections. For mild acute osteomyelitis that has responded well, antibiotics should be continued for at least 4 weeks. For severe chronic osteomyelitis that has been difficult to control, antibiotic administration may continue for up to 6 months.

Osteomyelitis of the mandible is a severe infection that may result in loss of a large portion of the mandible. Therefore a clinician who has the training and experience to handle the problem expeditiously should manage this infection. In addition, it is likely that medical consultation will be required to help correct any underlying compromise of host defenses.

ACTINOMYCOSIS

Actinomycosis is a relatively uncommon infection of the soft tissues of the jaws. It is usually caused by *Actinomyces israelii* but may also be caused by *A. naeslundii* or *A. viscosus*. *Actinomyces* is an endogenous bacterium of the oral cavity that was once thought to be an anaerobic fungus. However, it has now been clearly established that actinomycetes are anaerobic bacteria.

Actinomycosis is a relatively uncommon disease, because the bacteria have a low degree of virulence. For the infection to become established, the bacteria must be inoculated into an area of injury or locally increased susceptibility, such as areas of recent tooth extraction, severely carious teeth, or minor oral trauma. The infec-

tion is primarily one of soft tissue and progresses by direct extension into adjacent tissues.

Unlike other infections, actinomycosis does not follow usual anatomic planes but rather burrows through them and becomes a lobular "pseudotumor." If the infection erodes through a cutaneous surface, which is common with orofacial actinomycosis, multiple sinus tracts typically develop. Once drainage is established, the patient has minimal pain, although the sinus tracts will continue to drain spontaneously until the infection is brought under control (Fig. 16-16).

A definitive diagnosis depends on laboratory identification. *Actinomyces* is an anaerobic bacterium and therefore must be incubated in an anaerobic environment, usually on brain-heart agar or blood agar, for 4 to 6 days. In up to 50% of all actinomycotic infections the organism is not grown. However, the clinical presentation of the patient with actinomycosis is characteristic. The patient has an atypical infection of the jaws that responds well to antibiotic therapy initially; however, after the antibiotic is stopped, the infection recurs. The patient with this disease has frequently had multiple episodes of recurrent infection in the same area.

Therapy of actinomycosis includes surgical I&D and excision of all sinus tracts. This portion of the treatment is important to ensure that adequate amounts of antibiotic are actually delivered to the infected area.

The antibiotic of choice for actinomycosis is penicillin in the nonallergic patient. The dose varies with the seriousness of the disease. The usual recommended dose is 500 mg 4 times a day for at least 3 months. The reason for the prolonged administration of the antibiotic is to prevent the recurrence of the infection. If the patient has had a serious infection or the bone of the jaws is involved, high doses of penicillin should be given parenterally while the patient is hospitalized. IV administration of 10 million units of penicillin daily in divided doses is continued until the disease is clinically cured; this ranges from 3 to 14

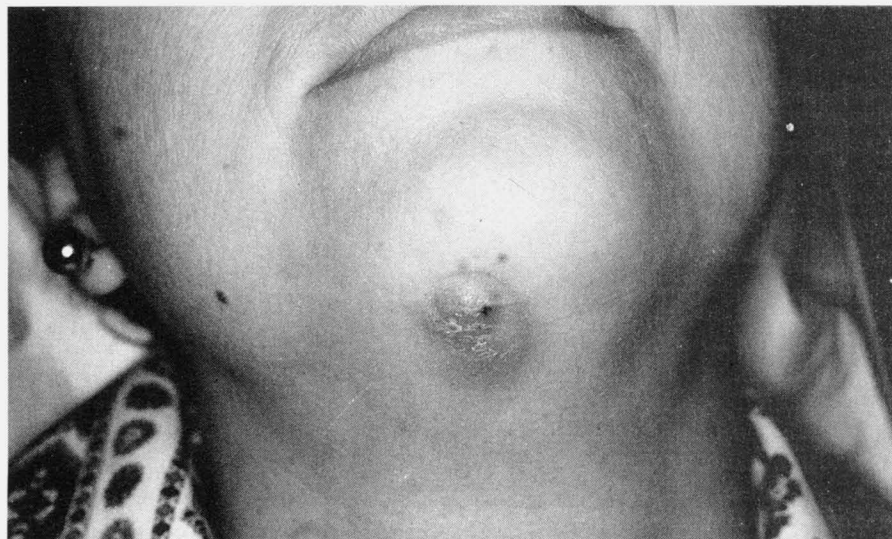

FIG. 16-16 This actinomycosis had multiple recurrences. The patient experienced a small amount of swelling with multiple small sinus tracts.

days. The patient is then discharged from the hospital, and a course of oral penicillin is begun.

The drug of second choice is tetracycline, with doxycycline being the preferred drug, because it can be administered once per day during the long-term antibiotic administration.

In summary, actinomycosis is an indolent infection that tends to erode through tissues rather than follow typical fascial planes and spaces. It is difficult to eradicate using short-term antibiotic regimens. Therefore I&D of any accumulation of pus and excision of chronic sinus tracts must be accomplished. Finally high-dose antibiotic administration is recommended for initial control of the infection, with long-term antibiotic therapy to prevent recurrence of actinomycosis.

CANDIDOSIS

The organism *Candida albicans* is a naturally occurring fungus in the oral cavity. It rarely causes disease unless the patient's health becomes compromised. The two most common causes of compromise are administration of antibiotics, especially penicillin, for prolonged periods and chemotherapy for leukemias and other forms of cancer. In these situations *Candida* organisms overgrow the oral cavity and cause a superficial infection, which usually appears intraorally as distinct white patches that can be easily rubbed off with gauze to expose an underlying red, raw surface (Fig. 16-17). *Candida* spp. can be easily cultured and diagnosed by their typical appearance on Gram's stain.

Angular cheilitis can be aggravated by the presence of *Candida* organisms. Most patients who have this problem are edentulous and overclosed and have a resultant chron-

ic wetness at the corner of the mouth and subsequent yeast growth.

Topical antifungal agents can usually deliver therapy for oral candidosis. The two most commonly used drugs for this purpose are (1) nystatin and (2) clotrimazole. Both of these drugs are prepared as lozenges and are delivered by sucking on the lozenge until it is totally dissolved. Nystatin is the preferred drug, because the chances for adverse reactions are essentially zero.

Clotrimazole has a quite small risk of toxicity and therefore is usually viewed as being a drug of second choice. The usual dose of either preparation is one lozenge 4 or 5 times per day for 2 weeks. Patients usually experience rapid resolution of the signs and symptoms of candidosis but must be informed that there will be a recurrence of the infection unless they continue the therapy for the entire 14 days. If the patient has a denture, the denture should be soaked in chlorhexidine overnight for the entire treatment.

Systemically administered drugs, such as fluconazole, can also treat oral candidosis. This antifungal drug is quite effective, especially in oropharyngeal candidosis, which is not responsive to topical therapy. Many authorities recommend that if topical therapy has failed (i.e., recurrence), then oral fluconazole 200 mg once daily for 10 days is the treatment of choice. Patient compliance is higher (1 pill versus 4 lozenges), so relapse is unusual.

It is important to remember that candidosis usually occurs only in medically compromised patients. Patients without histories of recent antibiotic therapy, cancer chemotherapy, or other types of immunocompromise should be suspected of having an underlying, undiagnosed immunocompromising disease. Predominant among these is acquired immunodeficiency syndrome (AIDS).

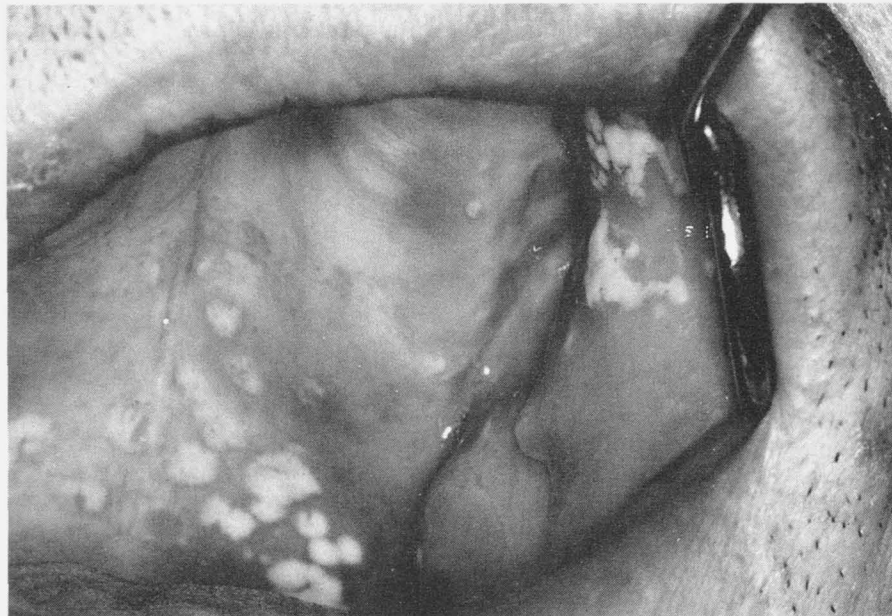

FIG. 16-17 Candidiasis of oral cavity appears as white patches on oral mucosa.

BIBLIOGRAPHY

- Barratt GE, Koopmann CF, Coulthand SW: Retropharyngeal abscess: a ten-year experience, *Laryngoscope* 94:455, 1984.
- Beck HJ et al: Life-threatening soft tissue infections of the neck, *Laryngoscope* 94:354, 1984.
- Bennhoff DF: Actinomycosis: diagnosis and therapeutic considerations and a review of 32 cases, *Laryngoscope* 94:1198, 1984.
- Dzyak WR, Zide MF: Diagnosis and treatment of lateral pharyngeal space infections, *J Oral Maxillofac Surg* 42:243, 1984.
- Fielding AF et al: Cavernous sinus thrombosis: report of a case, *J Am Dent Assoc* 106:342, 1983.
- Finkelstein M, Vincent S: Management of mucosal and related dermatologic disorders. In Peterson LJ, editor: *Principles of oral and maxillofacial surgery*, Philadelphia, 1992, JB Lippincott.
- Giordano AM et al: Chronic osteomyelitis following mandibular fracture and its treatment, *Arch Otolaryngol* 108:30, 1982.
- Hall BB, Fitzgerald RH, Rosenblatt JE: Anaerobic osteomyelitis, *J Bone Joint Surg* 64A:30, 1983.
- Haug RH, Picard U, Indresano AT: Diagnosis and treatment of the retropharyngeal abscess in adults, *J Oral Maxillofac Surg* 28B:34, 1990.
- Karlin RJ, Robinson WA: Septic cavernous sinus thrombosis, *Ann Emerg Med* 13:449, 1984.
- Marciani RD: Clinical considerations in head and neck infections. In Peterson LJ, editor: *Principles of oral and maxillofacial surgery*, Philadelphia, 1992, JB Lippincott.
- Meanier F, Aoun M, Gerard M: Therapy for oropharyngeal candidiasis in the immunocompromised host: a randomized double blind study of fluconazole vs. ketoconazole, *Rev Infect Dis* 12:5364, 1990.
- Patterson HC, Kelly JH, Strome M: Ludwig's angina: an update, *Laryngoscope* 92:370, 1982.
- Peterson LJ: Odontogenic infections. In Cummings CW et al, editors: *Otolaryngology: head and neck surgery*, ed 3, St Louis, 1998, Mosby.
- Peterson LJ: Principles of antibiotic therapy. In Topazian RG, Goldberg MH, editors: *Management of oral and maxillofacial infections*, ed 2, Philadelphia, 1987, WB Saunders.
- Range A, Ruud A: Osteomyelitis of the jaws, *Int J Oral Surg* 7:523, 1978.
- Schechtman LV et al: Clotrimazole treatment of oral candidiasis in patients with neoplastic disease, *Am J Med* 76:91, 1984.
- Virolainen E et al: Deep neck infections, *Int J Oral Surg* 8:407, 1979.