

Principles of Endodontic Surgery

Richard E. Walton



CHAPTER



CHAPTER OUTLINE

DRAINAGE OF AN ABSCESS

PERIAPICAL SURGERY

Indications

- Anatomic Problems
- Restorative Considerations
- Horizontal Root Fracture
- Irretrievable Material in Canal
- Procedural Error
- Large Unresolved Lesions After Root Canal Treatment

Contraindications (or Cautions)

- Unidentified Cause of Treatment Failure
- When Conventional Root Canal Treatment is Possible
- Simultaneous Root Canal Treatment and Apical Surgery
- Anatomic Considerations
- Poor Crown and Root Ratio
- Medical (Systemic) Complications

Surgical Procedure

- Flap Design
- Semilunar Incision
- Submarginal Incision
- Full Mucoperiosteal Incision
- Anesthesia
- Incision and Reflection
- Periapical Exposure
- Curettage
- Root End Resection
- Root End Preparation and Restoration
- Root End-Filling Materials

Irrigation

- Radiographic Verification
- Flap Replacement and Suturing
- Postoperative Instructions
- Suture Removal and Evaluation

CORRECTIVE SURGERY

Indications

- Procedural Errors
- Resorptive Perforations

Contraindications

- Anatomic Considerations
- Location of Perforation
- Accessibility

Considerations

- Surgical Approach
- Repair Material
- Prognosis

Surgical Procedure

HEALING

RECALL

ADJUNCTS

- Light and Magnification Devices
- Surgical Microscope
- Fiber Optics

Guided Tissue Regeneration

Bone Augmentation

WHEN TO CONSIDER REFERRAL

- Training and Experience
- Determining the Cause of Root Canal Treatment Failure

Surgical Difficulties

Endodontic surgery is the management or prevention of periradicular pathosis by a surgical approach. In general, this includes abscess drainage, periapical surgery, corrective surgery, intentional replantation, and root removal (Box 17-1).

Surgery has traditionally been an important part of endodontic treatment. However, until recently there was little research on indications and contraindications, techniques, success and failure (i.e., long-term prognosis), wound healing, and materials and devices to augment procedures. Because of this lack of information, many surgeries were performed for the wrong reasons, such as the routine correcting of failed root canal treatment, removing of large lesions believed to be cysts, or the performing of single-visit root canal treatment. Indeed, on occasion, *a surgical approach is clearly indicated, but few situations exist in which surgery is required.* Other modalities, such as root canal treatment or retreatment, may be preferred. However, when surgery is required, it must adhere to basic endodontic principles, that is, the assessing and obtaining of adequate débridement and obturation of the canal or canals.¹

Root canal treatment is generally a successful procedure if the problem is accurately diagnosed and careful technique is used. A common misconception is that if conventional root canal treatment fails, surgery is indicated for correction. Usually this is not true; most failures are better managed by retreatment.² At other times surgery is necessary to correct a failure or, for other reasons, may be the only alternative to extraction.

The purpose of this chapter is to present the indications and contraindications for endodontic surgery, the diagnosis and treatment planning, and the basics of endodontic surgical techniques. Most of the procedures presented should be performed by specialists, or on occasion, by experienced generalists. However, the general dentist must be skilled in diagnosis and treatment planning and able to recognize which procedures are indicated in particular situations. When a patient is to be referred to a specialist for treatment, the general dentist must have knowledge sufficient to describe the surgical procedure. In addition, the generalist should assist in the follow-up care and long-term assessment of treatment outcomes.

The procedures discussed in this chapter are drainage of an abscess, apical (i.e., periradicular) surgery, and corrective surgery.

DRAINAGE OF AN ABSCESS

Drainage releases purulent or hemorrhagic transudates and exudates from a focus of liquefaction necrosis (i.e., abscess). Draining the abscess relieves pain, increases circulation, and removes a potent irritant. The abscess may be confined to bone or may have eroded through bone and periosteum to invade soft tissue. Managing these intraoral or extraoral swellings by incision for drainage is reviewed in Chapters 15 and 16.

An abscess in bone may be drained by two methods: One is by opening into the offending tooth to obtain drainage through the canal; the abscess often does not

BOX 17-1

Categories of Endodontic Surgery

- Abscess drainage
- Periapical surgery
- Hemisection/root amputation
- Intentional replantation
- Corrective surgery

BOX 17-2

Indications for Periapical Surgery

- Anatomic problems preventing complete débridement/obturation
- Restorative considerations that compromise treatment
- Horizontal root fracture with apical necrosis
- Irretrievable material preventing canal treatment or retreatment
- Procedural errors during treatment
- Large periapical lesions that do not resolve with root canal treatment

communicate with the apex. The other suggested approach to manage an abscess in bone is called *trephination*. This is done by attempting to create a pathway with a bur or rotary instrument through gingiva and cortical bone, directly into the abscess. This approach is of questionable effectiveness.³

PERIAPICAL SURGERY

Periapical (i.e., periradicular) surgery includes resection of a portion of the root that contains undébrided or unobturated (or both) canal space. It can also involve reverse filling and sealing of the canal when conventional root canal treatment is not feasible. It is often performed in conjunction with apical curettage for reasons explained later in this chapter.

Indications

The success of apical surgery varies considerably, depending on the reason for and nature of the procedure. With failed root canal treatment, often retreatment is not possible or a better result cannot be achieved by a coronal approach.⁴ If the cause of the failure cannot be identified, surgical exploration may be necessary (Fig. 17-1). On occasion an unusual entity in the periapical region requires surgical removal and biopsy for identification (Fig. 17-2). Those indications for periapical surgery are discussed in the following sections (Box 17-2).

Anatomic problems. Calcifications or other blockages, severe root curvatures, or constricted canals (i.e., calcific metamorphosis) may compromise root canal treatment, that is, prevent instrumentation, obturation,

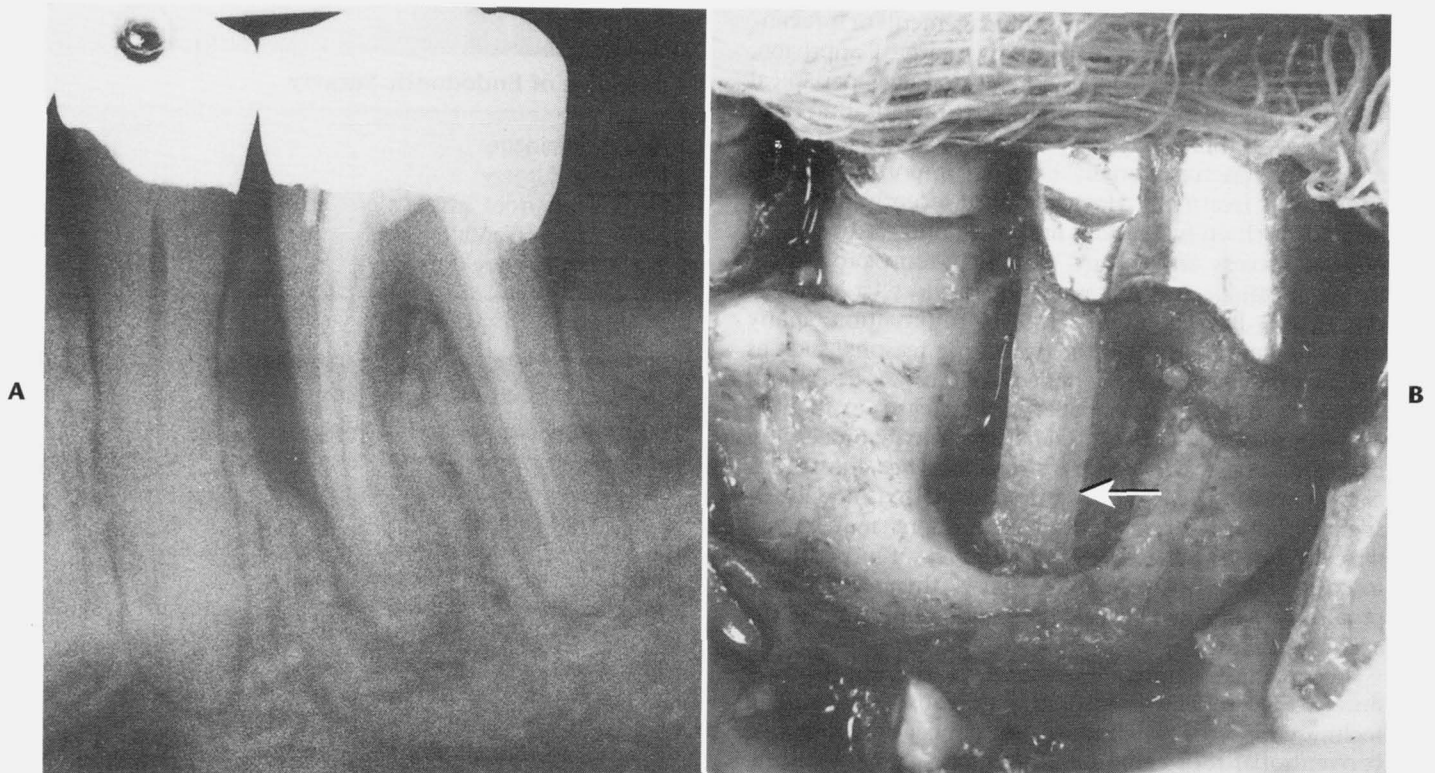


FIG. 17-1 Surgical exploration. **A**, Periradicular lesion on mesial root may be caused by perforation, incomplete débridement (lateral and apical), or vertical root fracture. **B**, Visualization after flap reflection shows vertical root fracture (arrow); root must be removed or tooth extracted. (Courtesy of Dr. L. Baldassari-Cruz, University of Iowa.)

or both (Fig. 17-3). Because a canal is always present (even if very small), failure to débride and obturate may lead to failure.

Although the outcome may be questionable, it is preferable to attempt conventional root canal treatment or retreatment before apical surgery.⁵ If this is not possible, removing or resecting the uninstrumented and unfilled portion of the root and placing a root end filling may be necessary.

Restorative considerations. Root canal treatment may be risky because of problems that may occur from attempting access through a restoration, such as through a crown on a mandibular incisor. An opening could compromise retention of the restoration or perforate the root. Rather than attempt the root canal treatment, root resection and root-end filling may be preferred to seal in irritants.

A common requirement for surgery is failed treatment on a tooth that has been restored with a post and core (Fig. 17-4). Many posts are difficult to remove or may cause root fracture during removal.

Horizontal root fracture. Occasionally, after a traumatic root fracture, the apical segment undergoes pulp necrosis. Because this cannot be predictably treated from a coronal approach, the apical segment is removed surgically after root canal treatment of the coronal portion (Fig. 17-5).

Irretrievable material in canal. Canals are occasionally blocked by objects such as separated instruments (Fig. 17-6), restorative materials, segments of posts, or

BOX 17-3

Contraindications (or Cautions) for Periapical Surgery

- Unidentified cause of root canal treatment failure
- When conventional root canal treatment is possible
- Combined coronal treatment/apical surgery
- When retreatment of a treatment failure is possible
- Anatomic structures (e.g., adjacent nerves and vessels) are in jeopardy
- Structures interfere with access and visibility
- Compromise of crown/root ratio
- Systemic complications (e.g., bleeding disorders)

other foreign objects. If evidence of apical pathosis is found, those materials must be removed surgically, usually with a portion of the root (Fig. 17-7).

Procedural error. Separated instruments, ledging, gross overfills, and perforations (Figs. 17-8 and 17-9 on pages 388 and 389, respectively) may result in failure. Although overfilling is not in itself an indication for removal of the material, surgical correction is frequently necessary in these situations.

Large unresolved lesions after root canal treatment. Occasionally, very large periradicular lesions do not heal or may even enlarge after adequate débridement and obturation. These are generally best resolved with

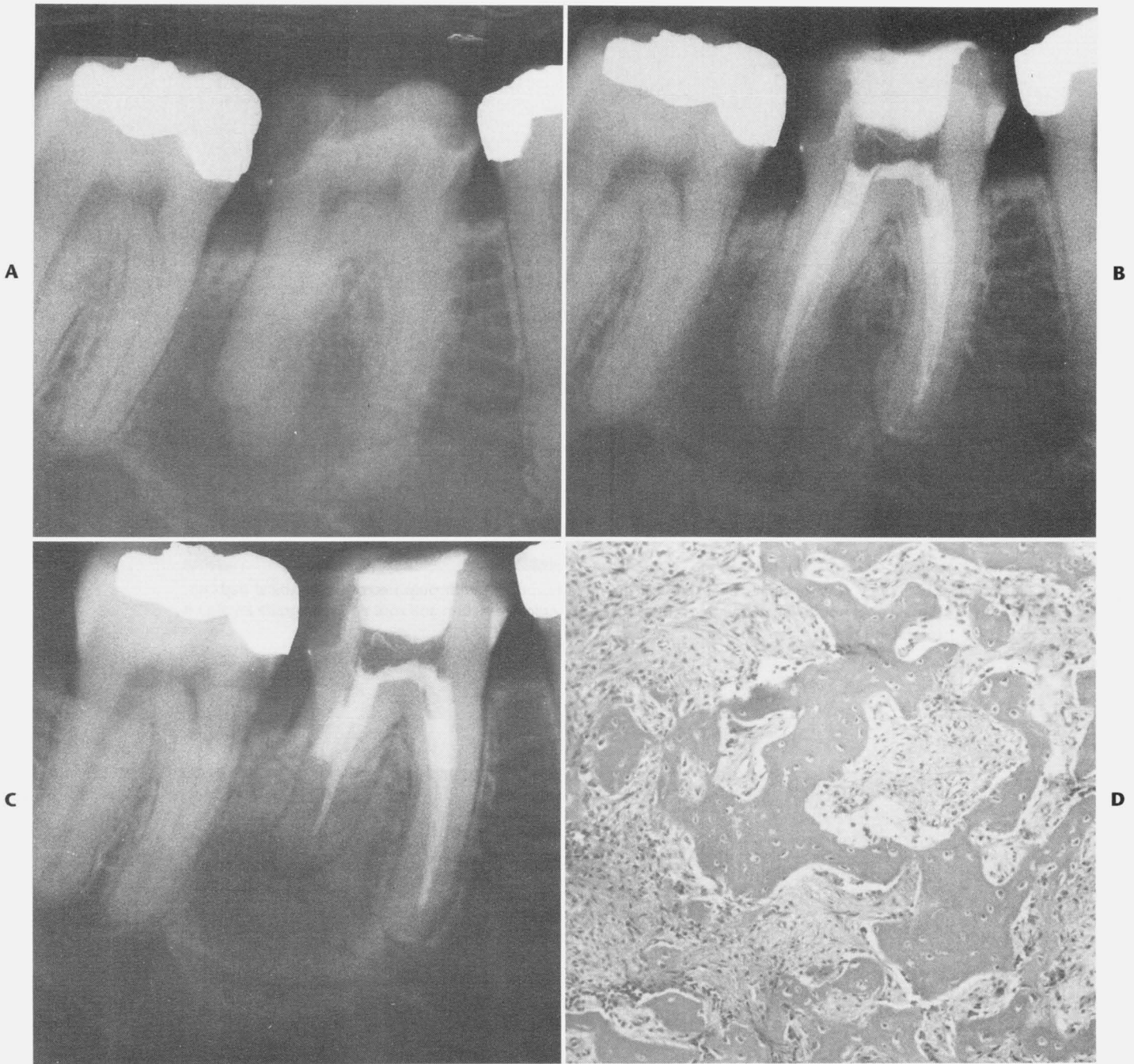


FIG. 17-2 Surgical removal of pathosis. **A**, Pulp is responsive; this indicates that radiolucent lesion is not endodontic (i.e., pulpal) in origin. **B**, Because roots must be resected while removing the lesion, root canal treatment is performed. **C**, Distal root is resected and lesion is excised. **D**, Biopsy shows this to be an ossifying fibroma.

decompression and not curettage, which may damage adjacent structures (Fig. 17-10 on page 390). Often, decompression alone is sufficient to manage these lesions; surgical correction (i.e., removal) is unnecessary.⁶

Contraindications (or Cautions)

If other options are available, periapical surgery may not be the preferred choice (Box 17-3).

Unidentified cause of treatment failure. Relying on surgery to try to correct all root canal treatment failures could be labeled indiscriminate. An important consideration is to *first*, identify the cause of failure, then *second*, design an appropriate corrective treatment plan. Usually, retreatment is indicated and will give the best chance of success. Surgery to correct a treatment failure for which the cause cannot be identified is often unsuccessful. Surgical management of all periapical pathoses, large peri-

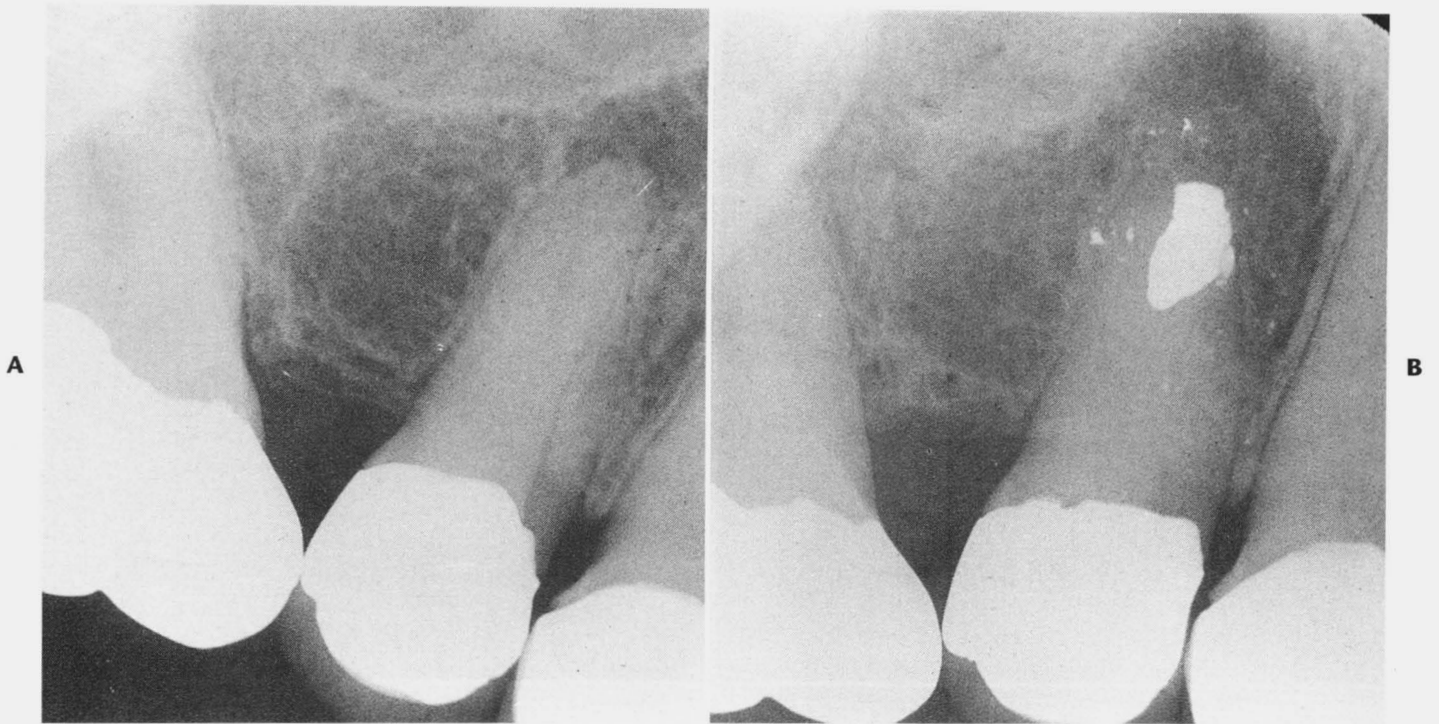


FIG. 17-3 A, Very small canal (i.e., calcific metamorphosis) with pulp necrosis and apical pathosis. Canal could not be located with occlusal access. B, Apical resection and root end retrograde amalgam to seal in irritants.

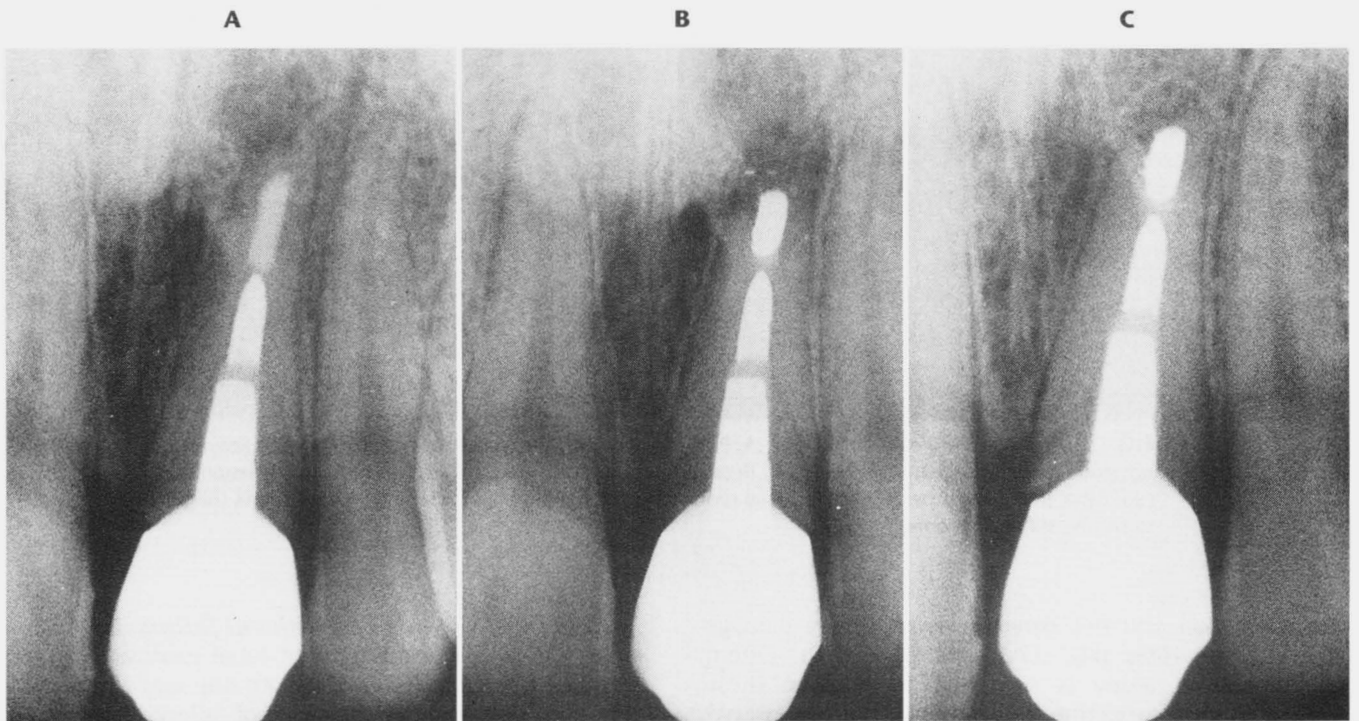


FIG. 17-4 A, Irretrievable fractured post and apical pathosis. B, Root end resection and filling with amalgam to seal in irritants, likely from coronal leakage. C, Regeneration of bone is evident after several months; prognosis is good.

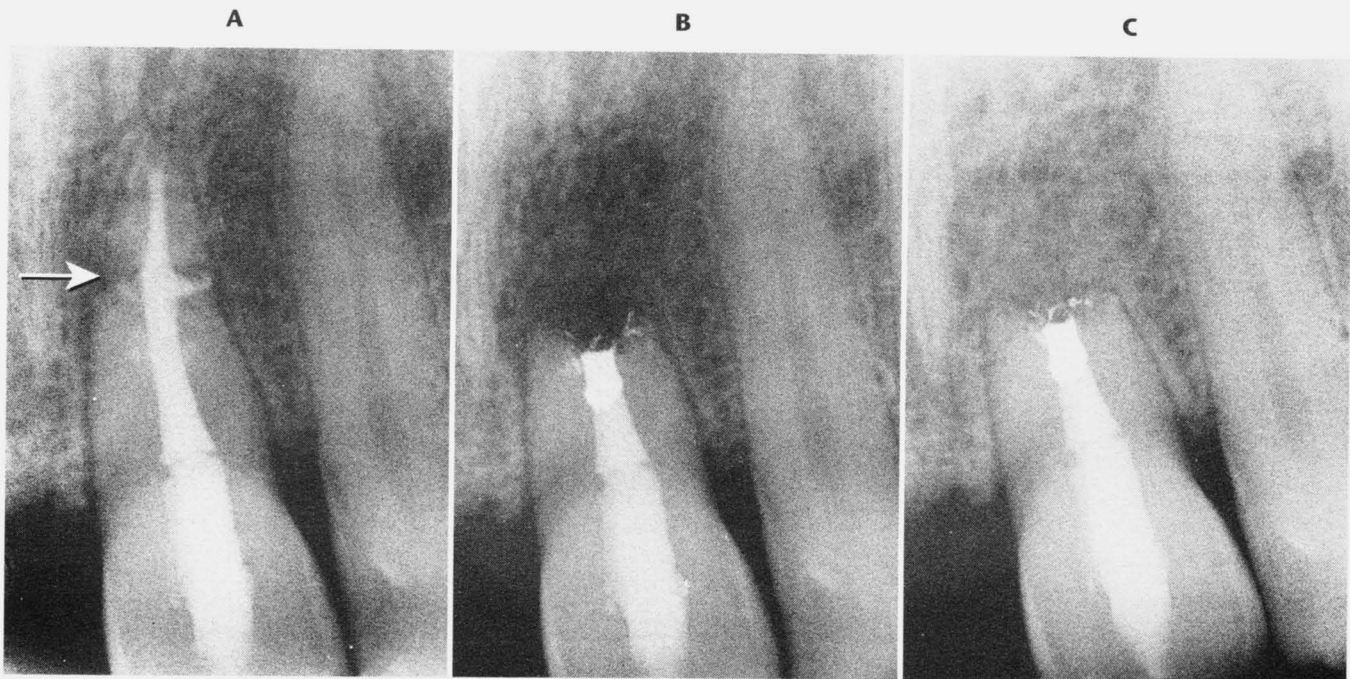


FIG. 17-5 A, Horizontal root fracture, with failed attempt to treat both segments. B, Apical segment is removed surgically and retrograde amalgam placed. C, Healing is complete after 1 year.

apical lesions, or both is often not necessary, because they will resolve after appropriate root canal treatment. This includes lesions that may be cystic; these also usually heal after root canal treatment.

When conventional root canal treatment is possible. In most situations orthograde conventional root canal treatment is preferred (Fig. 17-11 on page 391).⁴ Surgery is not indicated just because débridement and obturation are in the same visit, although there has been a long-held, incorrect notion that single-visit should be accompanied by surgery, particularly if a periradicular lesion is present.

Simultaneous root canal treatment and apical surgery. Few situations occur in which simultaneous root canal therapy and apical surgery is indicated. Usually, an approach that includes both of these as a single procedure has no advantages. It is preferable, and likely will result in better success, to perform only the conventional treatment without the adjunctive apical surgery. Another consideration is posttreatment symptoms. The level and incidence of pain after apical surgery is higher as compared with root canal treatment.⁷

Anatomic considerations. Most oral structures do not interfere with a surgical approach but must be considered. An example is the maxillary sinus, which may become exposed. Creating a sinus opening is neither unusual nor dangerous. However, caution is necessary to not introduce foreign objects into the opening and to remind the patient not to exert pressure by forcibly blowing the nose until the surgical wound has healed (in 1 to 2 weeks).

Bony structures generally do not contraindicate surgery, with the exception of the external oblique ridge over the mandibular second and third molars. In most cases this structure prevents adequate access to the root

apices; periapical surgery of these teeth is often not feasible. Other approaches, such as intentional replantation (Fig. 17-12 on page 392), may be indicated. The zygomatic buttress may inhibit access to maxillary molar apices. A prominent chin creates a shallow vestibule with limited access to mandibular anteriors. The mental foramen is of concern but is easily avoided by identifying its position radiographically and during flap reflection.

Poor crown and root ratio. Teeth with very short roots have compromised bony support and are poor candidates for surgery; root end resection in such cases may compromise stability. However, shorter roots may support a relatively long crown if the surrounding cervical periodontium is healthy (see Fig. 17-5).

Medical (systemic) complications. The general health and condition of the patient are always essential considerations. No specific contraindications for endodontic surgery exist that would not be similar to those for other types of oral surgical procedures.

Surgical Procedure

The following eleven steps, with modifications as appropriate, make up the typical approach: (1) flap design, (2) incision and reflection, (3) access to the apex, (4) curettage, (5) root end resection, (6) root end preparation and filling, (7) radiographic verification, (8) flap replacement and suturing, (9) postoperative instructions, (10) suture removal, and (11) long-term evaluation. This sequence is shown in Fig. 17-13 on page 393.

Flap design. A properly designed and carefully reflected flap will result in good access and uncomplicated healing.⁸ The basic principles of flap design should be followed; these are detailed in Chapter 8. Although several

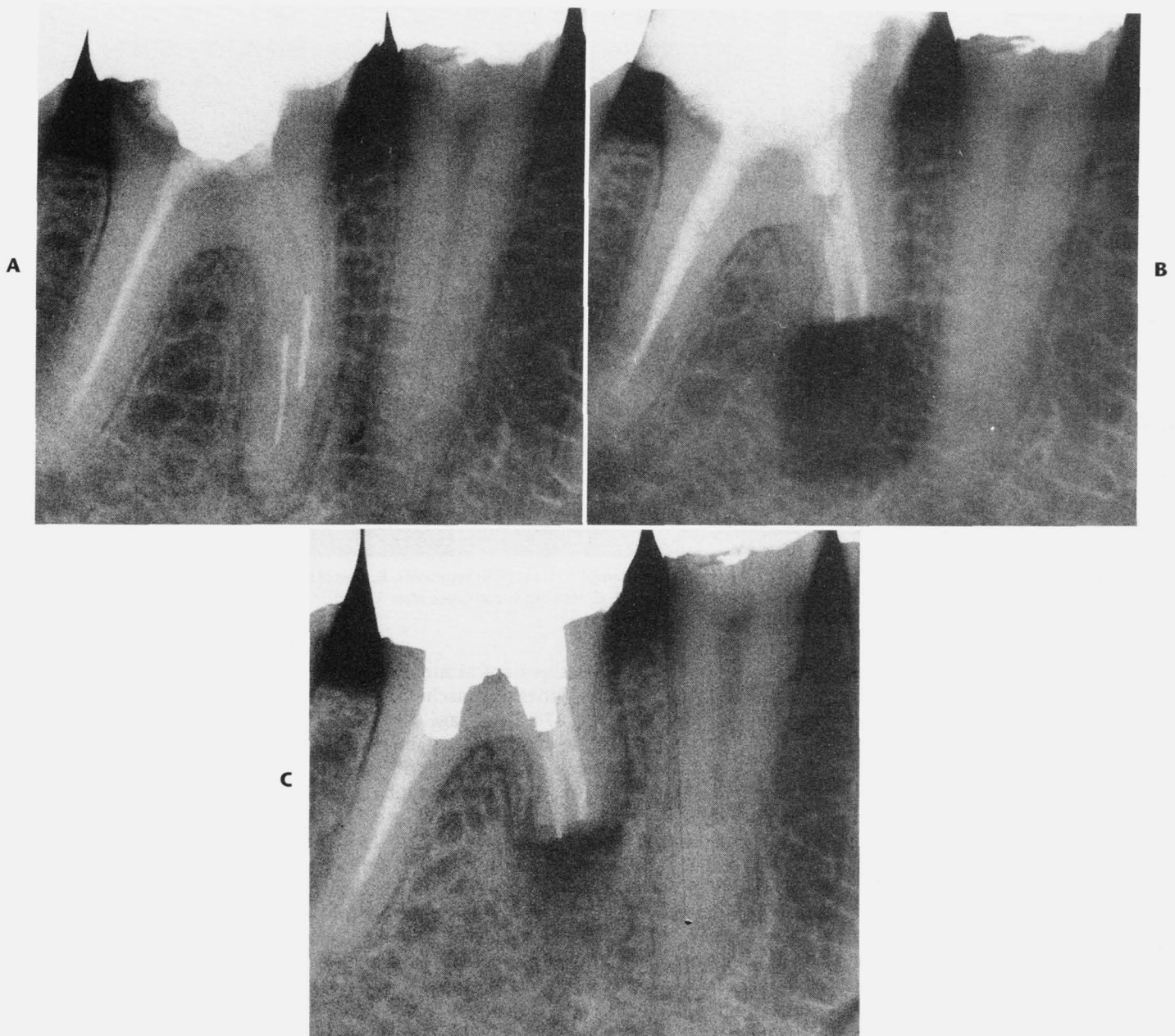


FIG. 17-6 A, Irretrievable separated instruments in mesial canals. B, After complete obturation, root is resected to level of obturation and to include files. C, Bone regeneration is occurring apically, but additional monitoring is necessary.

possibilities exist, the three most common incisions are (1) submarginal curved (i.e., semilunar), (2) submarginal, and (3) full mucoperiosteal (i.e., sulcular). The submarginal and full mucoperiosteal incision will have either a three-corner (i.e., triangular) or four-corner (i.e., rectangular) design.

Semilunar incision. This is a slightly curved half-moon horizontal incision in the alveolar mucosa (Fig. 17-14 on page 394). Although the location allows easy reflection, access to the periradicular structures is restricted. Other disadvantages to this incision include excessive hemorrhage, delayed healing, and scarring; this design is contraindicated for endodontic surgery.

Submarginal incision. The horizontal component is in attached gingiva with one or two accompanying vertical incisions (Fig. 17-15 on page 394). Generally the incision is scalloped in the horizontal line, with obtuse angles at the corners. It is used most successfully in the maxillary anterior region or, occasionally, with maxillary premolars with crowns. Because of the design, prerequisites are at least 4 mm of attached gingiva and good periodontal health.

The major advantage is esthetics. Leaving the gingiva intact around the margins of crowns is less likely to result in bone resorption with tissue recession and crown margin exposure. Compared with the semilunar inci-

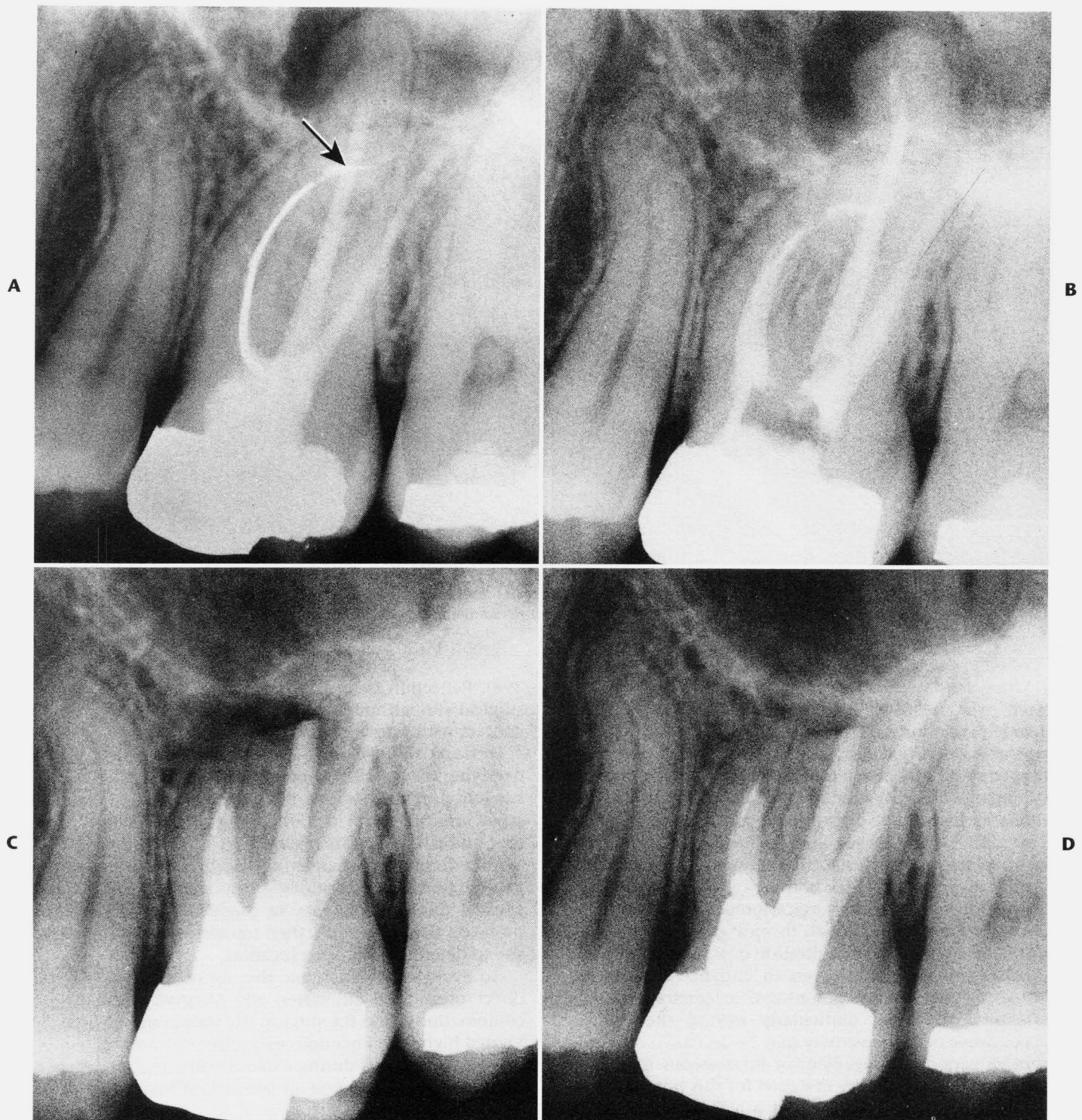


FIG. 17-7 A, Irretrievable material in mesial and lingual canals and apical pathosis. B, Canals are retreated but there is failure. C, Treatment is root end resection to level of gutta-percha in the mesial and lingual aspects. D, After 2 years, healing is complete.

sion, the submarginal provides less risk of incising over a bony defect and provides better access and visibility. Disadvantages include hemorrhage along the cut margins into the surgical site and occasional healing by scarring, compared with the full mucoperiosteal sulcular incision.

Full mucoperiosteal incision. This is an incision into the gingival sulcus, extending to the gingival crest (Fig. 17-16 on page 394). This procedure includes elevation of interdental papilla, free gingival margin, attached gingiva, and alveolar mucosa. One or two vertical relaxing incisions may be used, creating a three- or four-corner design.

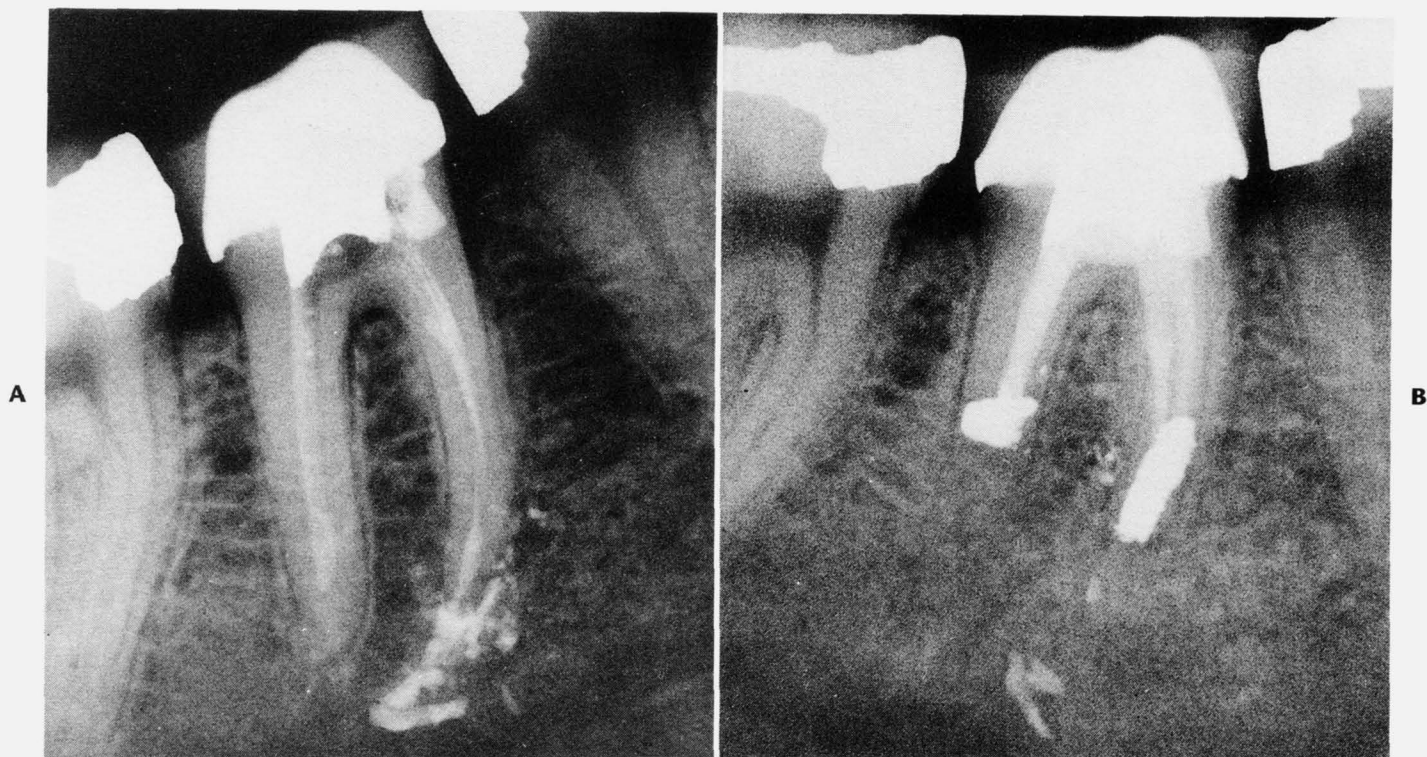


FIG. 17-8 **A**, Overfill of injected obturating material has resulted in pain and paresthesia as a result of damage to inferior alveolar nerve. **B**, Corrected by retreatment, then apicectomy, curettage, and a root end amalgam fill.

When feasible the full mucoperiosteal design is preferred over the other two techniques. The advantages include maximum access and visibility, not incising over the lesion or bony defect, less tendency for hemorrhage, complete visibility of the root, allowance of root planing and bone contouring, and reduced likelihood of healing with scar formation. The disadvantages are somewhat more difficult to replace and to suture; also, gingival recession frequently develops, exposing crown margins or cervical root surfaces (or both).

Anesthesia. For most surgical procedures, anesthetic approaches are conventional. In most regions a block is administered; then local infiltration of an anesthetic with 1:50,000 epinephrine is given to enhance hemostasis. Frequently, the patient is sensitive to curettage of the inflammatory tissue, particularly toward the lingual aspect. Some of the sensitivity may be decreased by a pre-emptive periodontal ligament or intraosseous injection, using a device specifically designed for this purpose.

A long-acting anesthetic agent is recommended, such as bupivacaine or etidocaine. Bupivacaine 0.5% with epinephrine 1:200,000 has been shown to give long-lasting anesthesia and, later, provide a lingering analgesia.⁹

Incision and reflection. A firm incision should be made through periosteum to bone. It is important to incise and reflect a full-thickness flap to minimize hemorrhage and to prevent tearing of the tissue. Reflection is with a sharp periosteal elevator beginning in the vertical incisions, then raising the horizontal component. To reflect the periosteum the elevator must firmly contact bone while the tissue is raised (Fig. 17-17 on page

394). Reflection is to a level adequate for access to the surgical site, although still allowing a retractor to have contact with bone.

Periapical exposure. Frequently, the cortical bone overlying the apex has been resorbed, exposing a soft tissue lesion. If the opening is small, it is enlarged using a large surgical round bur, until approximately half the root and the lesion are visible (Fig. 17-18 on page 395). With a limited bony opening, radiographs are used in conjunction with root and bone topography to locate the apex. A measurement may be made with a periodontal probe on the radiograph, then transferred to the surgical site to determine the apex location.

To avoid air emphysema, the use of handpieces that direct pressurized air, water, and abrasive particles (or combinations) into the surgical site should not be used.¹⁰ Vented high-speed handpieces or electrical surgical handpieces are preferred during osseous entry, root end resection, or both. Sealed-end air-pressurized handpieces also direct air away from the surgical site. Regardless of the handpiece used, there should be copious irrigation with a syringe or through the handpiece with sterile saline solution.¹¹ Enough overlying bone should be removed to expose the area around the apex and at least half the length of the root. Good access and visibility are important; the bony window must be adequate.

Curettage. Most of the granulomatous, inflamed tissue surrounding the apex should be removed (Fig. 17-19 on page 395) to gain access and visibility of the apex, to obtain a biopsy for histologic examination (when indicated), and to minimize hemorrhage.

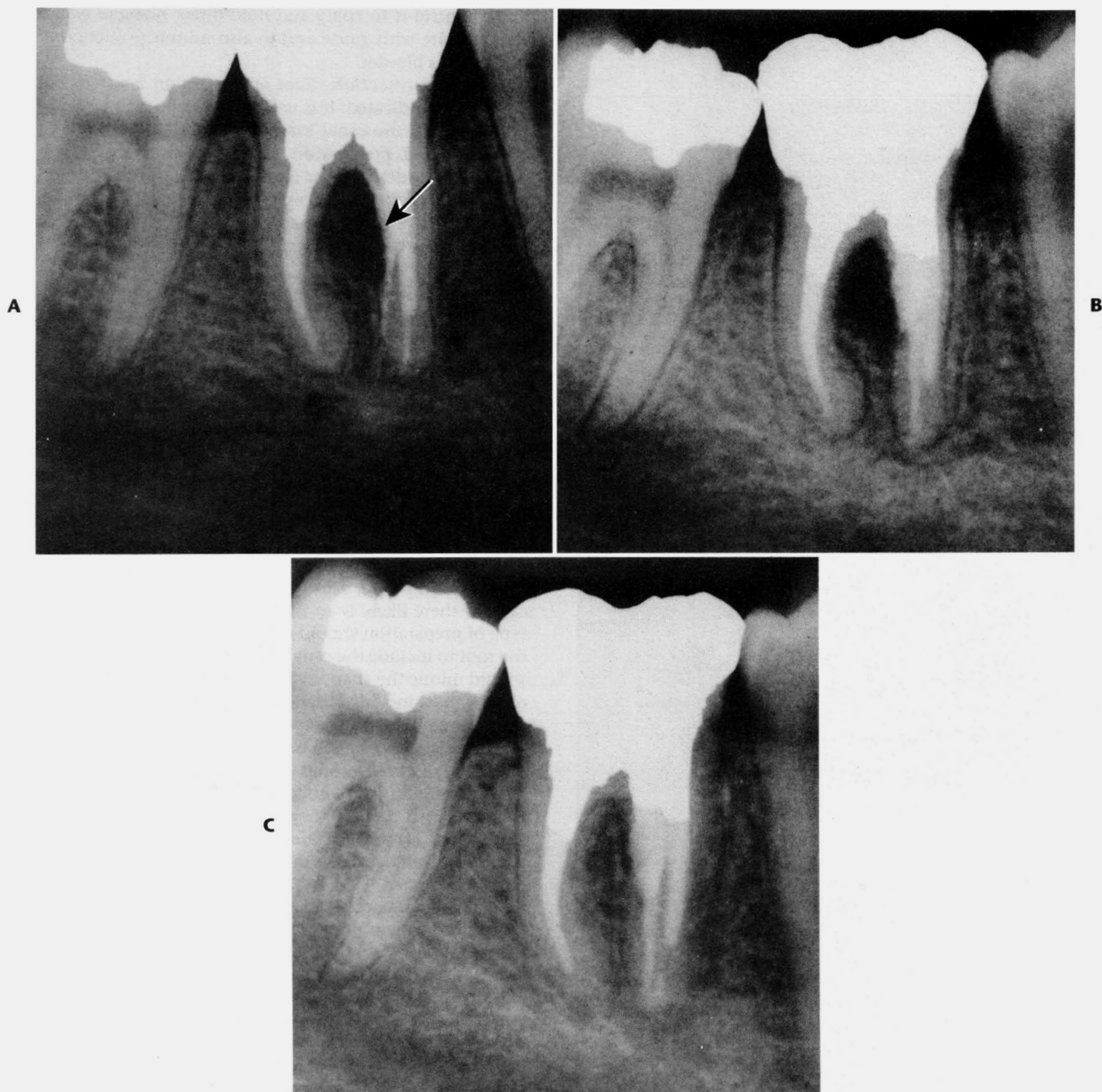


FIG. 17-9 Repair of perforation. A, Furcation perforation results in extrusion of material (arrow) and pathosis. B, After flap reflection and exposure, the defect is repaired with mineral trioxide aggregate (MTA). C, Evaluation at 2 years shows successful healing. (Courtesy Dr. L. Baldassari-Cruz, University of Iowa.)

If possible the tissue should be enucleated in one piece with a suitably sized sharp curette, although total lesion removal usually does not occur. A cleaner bony cavity will have the least hemorrhage and the best visibility. Tissue removal should not jeopardize the blood supply to an adjacent tooth. In addition, some areas of the lesion may be inaccessible to the curettes, such as on the lingual

aspect of the root. Portions of inflamed tissue or epithelium may be left, without compromising healing; total removal is not necessary.¹²

If hemorrhage from soft or hard tissue is excessive to the extent that visibility is compromised, homeostatic agents or other control techniques are useful.¹³ These agents should be removed after use.¹⁴ The best hemor-

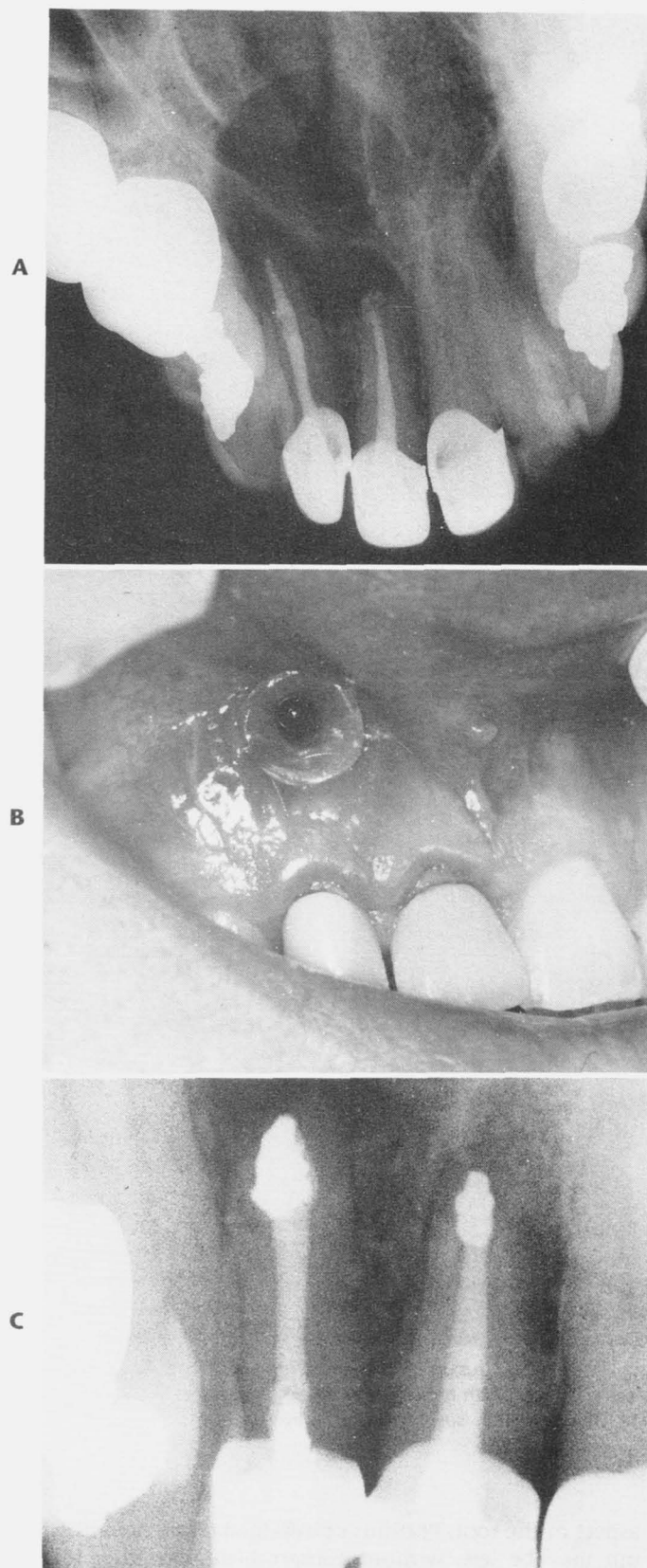


FIG. 17-10 Decompression of large lesion. A, Extensive periradicular lesion failed to resolve. Coronal leakage in either treated tooth is possible. B, Surgical opening is created to defect; polyethylene tube extends into lesion to promote drainage. C, After partial resolution, root end resection and filling with amalgam are performed.

rhage control is to apply and hold direct pressure over a bleeding site with gauze and to also minimize suction at the site of a bleeder.

Root end resection. Root end resection is often, but not always, indicated. It is useful in two situations: (1) to gain access to the canal for examination and placement of a root end preparation and restoration and (2) to remove an undébrided or unobtured (or both) portion of a root. This may be necessary in cases with dilacerated roots, ledged or blocked canals, or apical canal space that is inaccessible because of restorations, as well as in accessing of lingual structures.

Before sectioning, a trough is created around the apex with a tapered fissure bur to expose and isolate the root end. The resecting is with the same tapered fissure bur. Depending on the location and whether a root end preparation is to be placed, a bevel of varying degrees is made in a faciolingual direction (Fig. 17-20 on page 396). The amount of root removed depends on the reason for performing the resection. Sufficient root apex must be removed to provide a larger surface and to expose additional canals. In general, approximately one half to one third of the root is resected—more if necessary for apical access; less if too much removal would further compromise stability of an already short root.

Root end preparation and restoration. This is indicated if there likely is an inadequate apical seal. A class 1 type of preparation should extend at least 3 to 4 mm into the root to include the canal. The shape of the preparation should mimic the shape of the cut surface of the root. The outline must include other canals and aberrations, such as an isthmus. Root end preparation may be done by slow-speed, specially designed microhandpieces (Fig. 17-21 on page 396) or by ultrasonic tips (Fig. 17-22 on page 397).¹⁵

Ultrasonic instruments offer some advantages of control and ease of use; they also permit less apical root removal in certain situations (Fig. 17-23 on page 397). Another advantage of the ultrasonic tips, particularly when diamond coated,¹⁶ is the formation of cleaner, better shaped preparation. Evidence suggests that success rates are significantly improved with ultrasonic preparation.¹⁷

Root end-filling materials. The root end-filling material is placed into the cavity preparation (Fig. 17-24 on page 398). These materials should seal well, be tissue tolerant, easily inserted, minimally affected by moisture, and visible radiographically. Importantly, the root end-filling material must be stable and nonresorbable indefinitely.

Amalgam (preferably zinc free), intermediate restorative material (IRM), and Super ethoxy benzoic acid (Super EBA) cement have been commonly used materials.¹⁸ Gutta-percha, composite resin, glass ionomer cement, IRM, Cavit, and different luting cements have also been recommended; these materials have less clinical documentation of success. Mineral trioxide aggregate (MTA) has shown favorable biologic¹⁹ and physical properties and ease of handling²⁰; it has become a widely used material.

No single, all-purpose, superior root end-filling material exists. Those that demonstrate the best combination of physical and biologic properties, as well as documentation of clinical success, are amalgam, MTA, composite resin and reinforced zinc oxide cements (e.g., IRM and

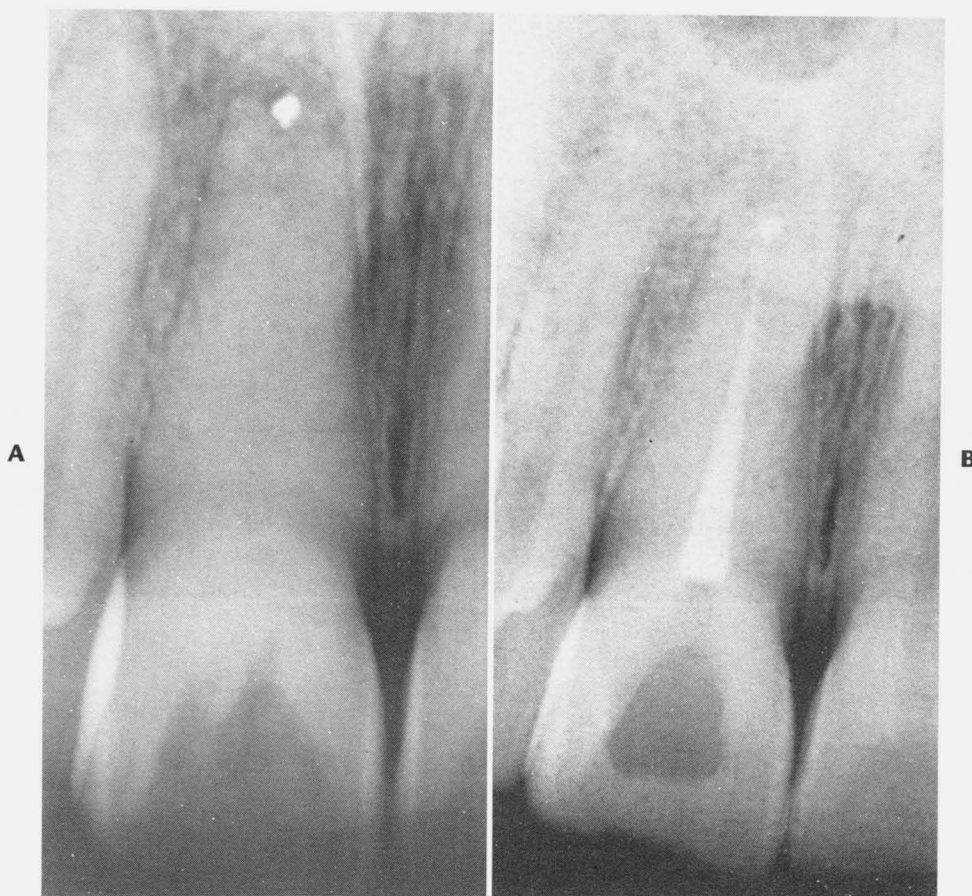

FIG. 17-11 This case is poorly done and done for the wrong reasons. **A**, Inadequate root end resection and root end filling does not seal apex. **B**, Root canal treatment is readily accomplished, with good chance of success.

Super EBA); one of these materials should be selected, according to the conditions.²¹ Amalgam should not be used if the field is bloody or if the root end preparation is less than 3 millimeters, or if access is limited. Composite resin with a bonding agent must be placed in a dry field. This material may be used in a shallow, concave preparation and has shown to be successful in molar root end surgeries.²² MTA, with its good properties, may be placed in a field in which some hemorrhage has occurred; the final set is not adversely affected by blood contamination. The long-term stability of MTA is unknown, because the material is relatively new. It likely has good longevity.

Each of these root end-filling materials has different, unique mixing and placement characteristics. The clinician should practice with each before placement in a patient.

Irrigation. The surgical site is flushed with copious amounts of sterile saline to remove soft and hard tissue debris, hemorrhage, blood clots and excess root end-filling material.

Radiographic verification. Before suturing, a radiograph is made to verify that the surgical objectives are satisfactory. If corrections are needed, these are made before suturing.

Flap replacement and suturing. The flap is returned to its original position and held with moderate digital

pressure and moistened gauze. This expresses hemorrhage from under the flap and gives initial adaptation and more accurate suturing. Silk sutures are generally used, although other materials are suitable, including 4-0 absorbable suture. Interrupted sutures are common, although both horizontal and vertical mattress and sling sutures are applicable in certain situations. After suturing, the flap should again be compressed digitally with moistened gauze for several minutes to express more hemorrhage. This encourages less postoperative swelling and more rapid healing.

Postoperative instructions. Both oral and written information should be supplied in simple, straightforward descriptions. The wording should minimize anxiety arising from normal postoperative sequelae by describing the ways in which the patient can promote healing and comfort. Instructions inform the patient of what to expect (i.e., swelling, discomfort, possible discoloration, and some oozing of blood) and the ways in which these sequelae can be prevented, managed, or both. The surgical site should not be disturbed, and pressure should be maintained (cold packs over the surgical area until bedtime might help). Oral hygiene procedures are indicated everywhere except the surgical site; careful brushing and flossing may begin after 24 hours. Proper nutrition and fluids are important but should not traumatize the area.

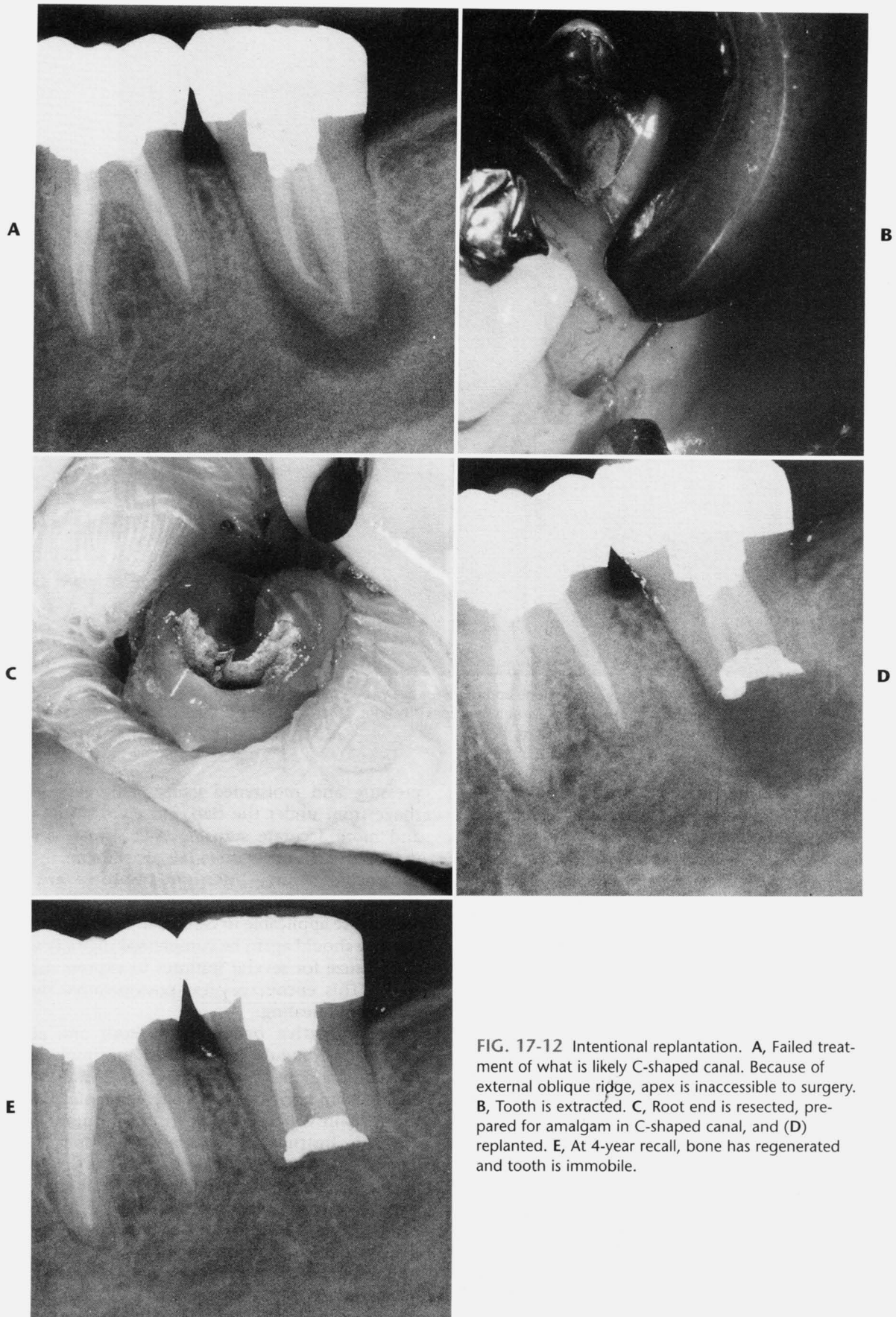


FIG. 17-12 Intentional replantation. **A**, Failed treatment of what is likely C-shaped canal. Because of external oblique ridge, apex is inaccessible to surgery. **B**, Tooth is extracted. **C**, Root end is resected, prepared for amalgam in C-shaped canal, and **(D)** replanted. **E**, At 4-year recall, bone has regenerated and tooth is immobile.

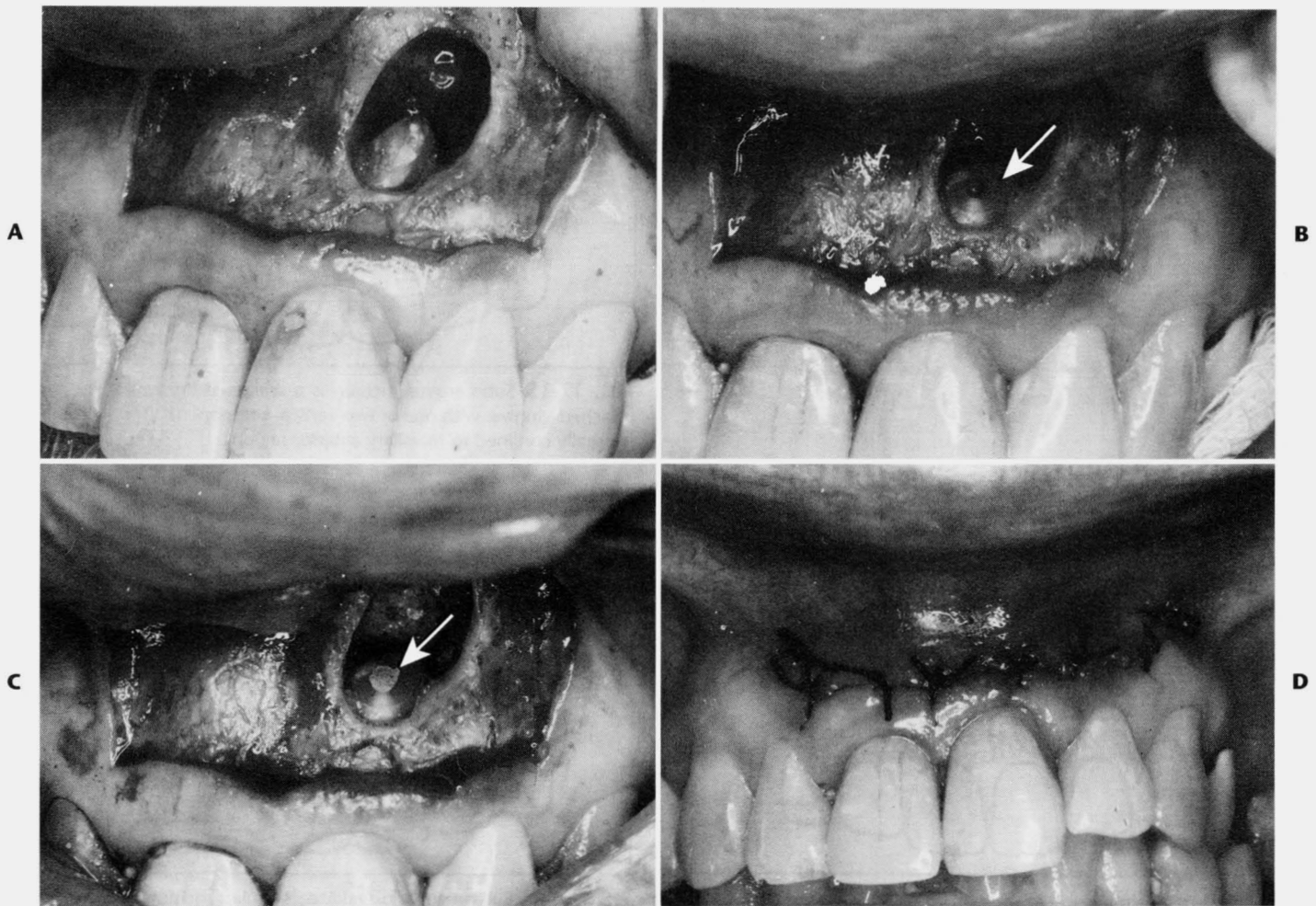


FIG. 17-13 Periapical surgical procedure. A, Submarginal incision, four-corner (i.e., rectangular), reflected flap. Large bony window is created to show apex. B, Root end is resected and prepared (arrow) for fill. C, Amalgam (arrow) has been condensed. D, Flap is replaced, compressed, and sutured (i.e., interrupted). (Courtesy Dr. T. Erickson, University of Iowa.)

A chlorhexidine rinse, twice daily, reduces bacterial count at the surgical site. This will minimize inflammation and enhance soft tissue healing.

Analgesics are recommended, although pain is frequently minimal; strong analgesics are usually not required. No category of pain medication is preferred; selection depends on the clinician and the patient. Analgesics for moderate pain will usually suffice and are most effective if administered before the surgery or at least before the anesthetic wears off. Antibiotics are not indicated as a prophylactic measure or even with a localized abscess²³; prescribing steroids has no demonstrated benefit.

The patient is instructed to call if excessive swelling or pain is experienced. Postoperative complications are a response to injury from the procedure; infection after this type of surgical procedure is rare. However, the patient should be evaluated in person if there are difficulties. Occasionally, sutures have torn loose, a foreign body (e.g., a cotton pellet) is under the flap, or an overreaction of the soft tissues takes place. Again, antibiotics would not be indicated; palliative or corrective treatment or tincture of time will usually suffice.

Suture removal and evaluation. Sutures ordinarily are removed in 3 to 6 days, with shorter periods being preferred to enhance healing. After 3 days swelling and discomfort should be decreasing. In addition, there should be evidence of primary wound closure; tissues that were reflected should be in apposition. Occasionally, a loose or torn suture may result in nonadapted tissue. In these cases the margins are readapted and resutured.

CORRECTIVE SURGERY

Corrective surgery is managing defects that have occurred by a biologic response (i.e., resorption) or iatrogenic (i.e., procedural) error. These may be anywhere on the root, from cervical margin to apex. Many are accessible; others are difficult to reach or are in virtually inaccessible areas. Usually, an injury or defect has occurred on the root. In response to the injury, there may be an inflammatory lesion or one may develop in the future. A corrective procedure is necessary. Generally, the procedure involves exposing, preparing, then sealing the defect. Usually included are removal of irritants and rebuilding the root surface (Box 17-4).

Text continues on page 397.

BOX 17-4

Corrective Surgery

Indications

Procedural errors (e.g., perforations)

Resorptive defects

Contraindications

Anatomic impediments

Inaccessible defect

Repair would create periodontal defect

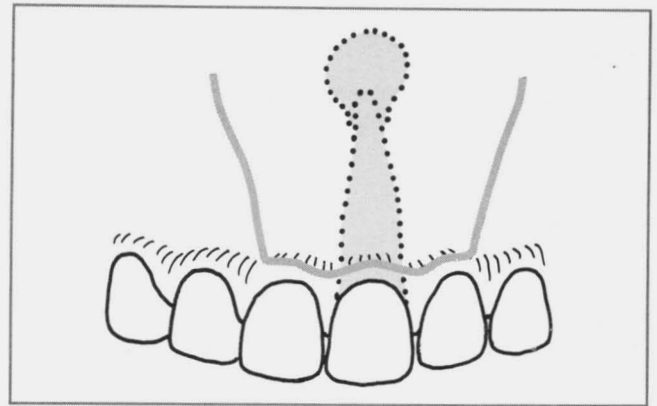


FIG. 17-15 Submarginal incision is a scalloped horizontal line in attached gingiva, with one or two vertical components. This incision is usually confined to maxillary anterior region.

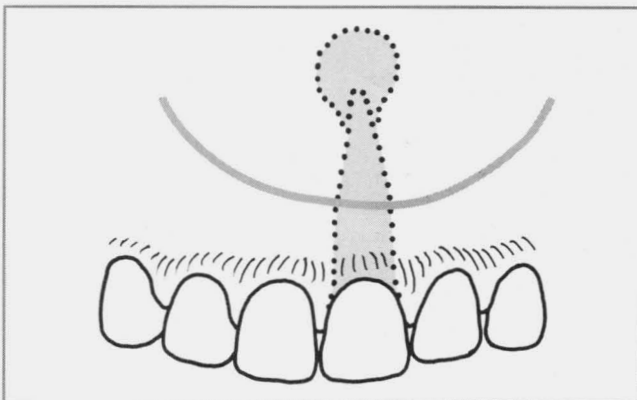


FIG. 17-14 Semilunar flap incision, primarily horizontal and in alveolar mucosa. Because of limitations of access and poorer healing, this design is contraindicated.

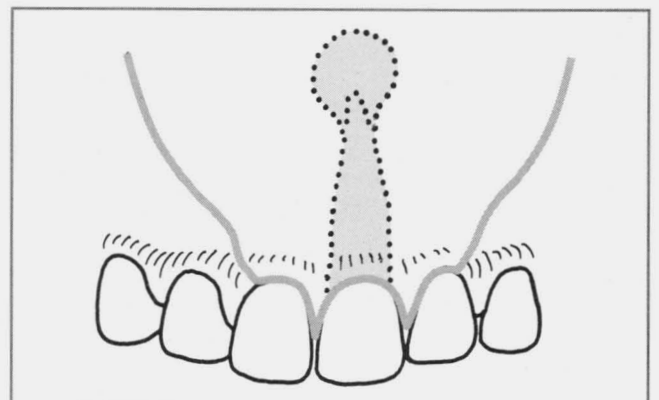


FIG. 17-16 Full mucoperiosteal (i.e., sulcular) incision. Horizontal incision is into sulcus, accompanied by one (i.e., three-corner) or two (i.e., four-corner) vertical components.

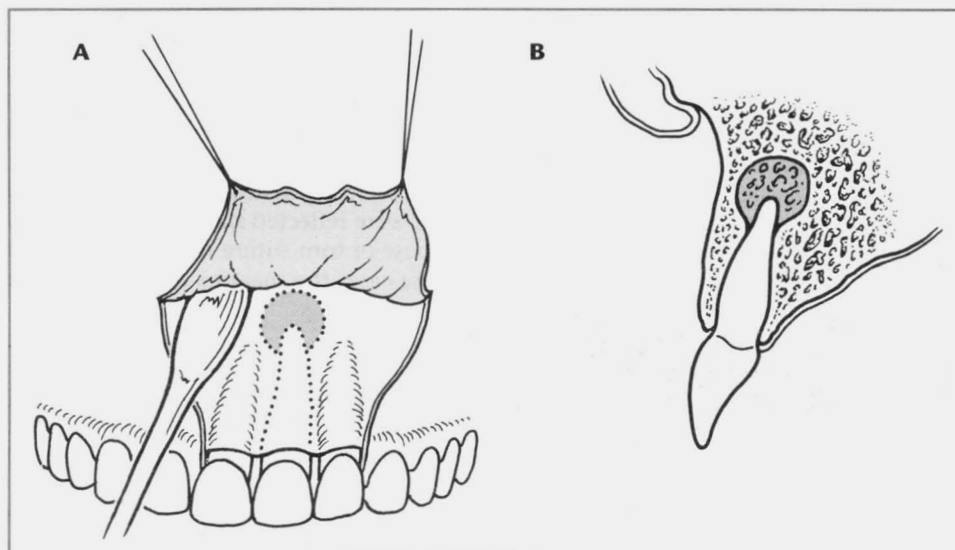


FIG. 17-17 Full-thickness flap is raised with sharp elevator in firm contact with bone. Enough tissue is raised to allow access and visibility to apical area. **A**, Frontal view. **B**, Cross-section.

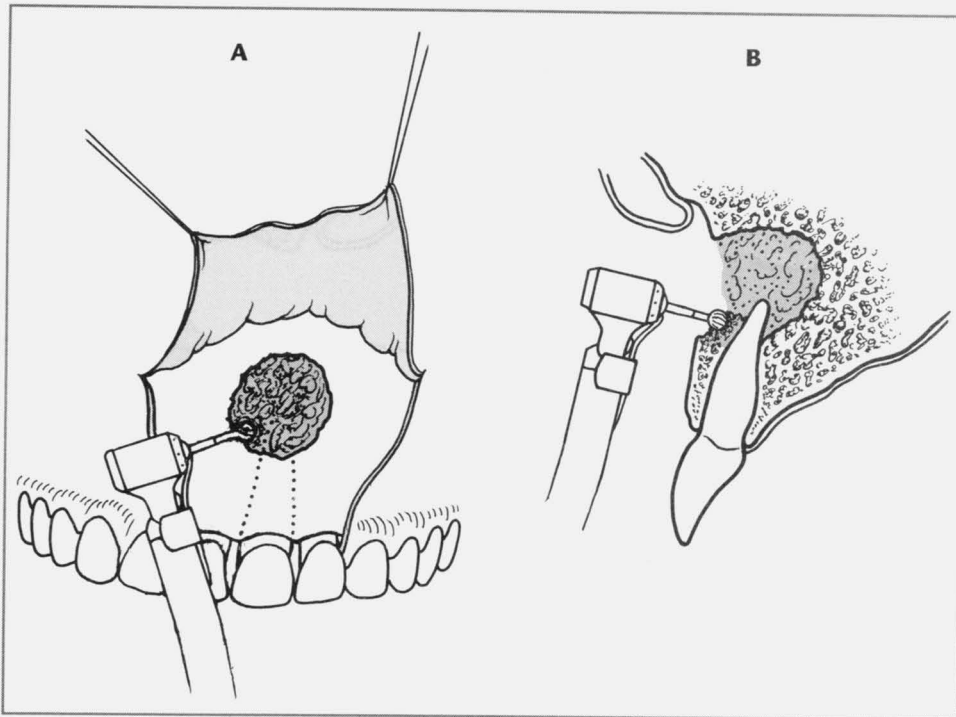


FIG. 17-18 Apical exposure. Large round bur is used to "paint" bony window. Enough is removed to give good visibility and access to lesion and apex. **A**, Frontal view. **B**, Cross-section.

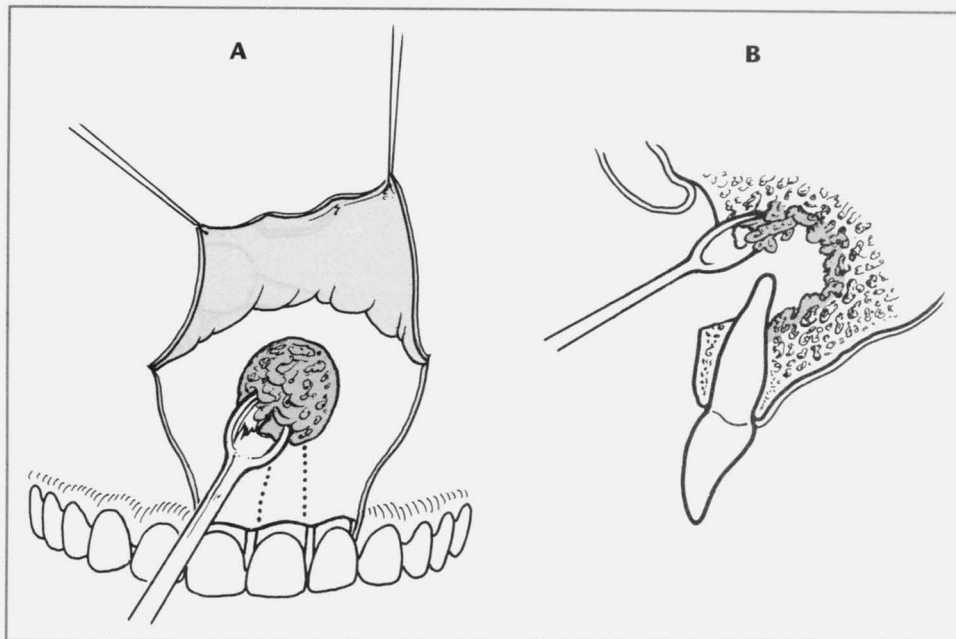


FIG. 17-19 Curettage. Much of lesion that is accessible is removed with large curettes. Usually, remnants of tissue remain, which is not a problem. **A**, Frontal view. **B**, Cross-section.

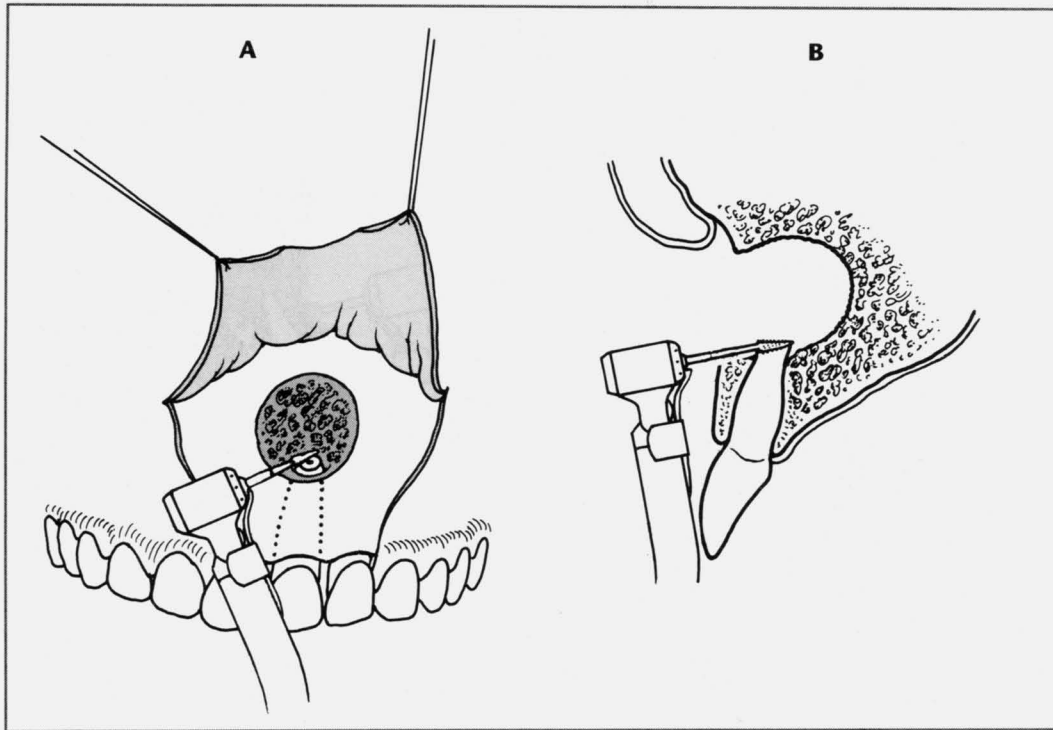


FIG. 17-20 Root end resection. Approximately one third of apex is removed with tapered bur. Amount removed and degree of bevel varies according to situation. A, Frontal view. B, Cross-section.

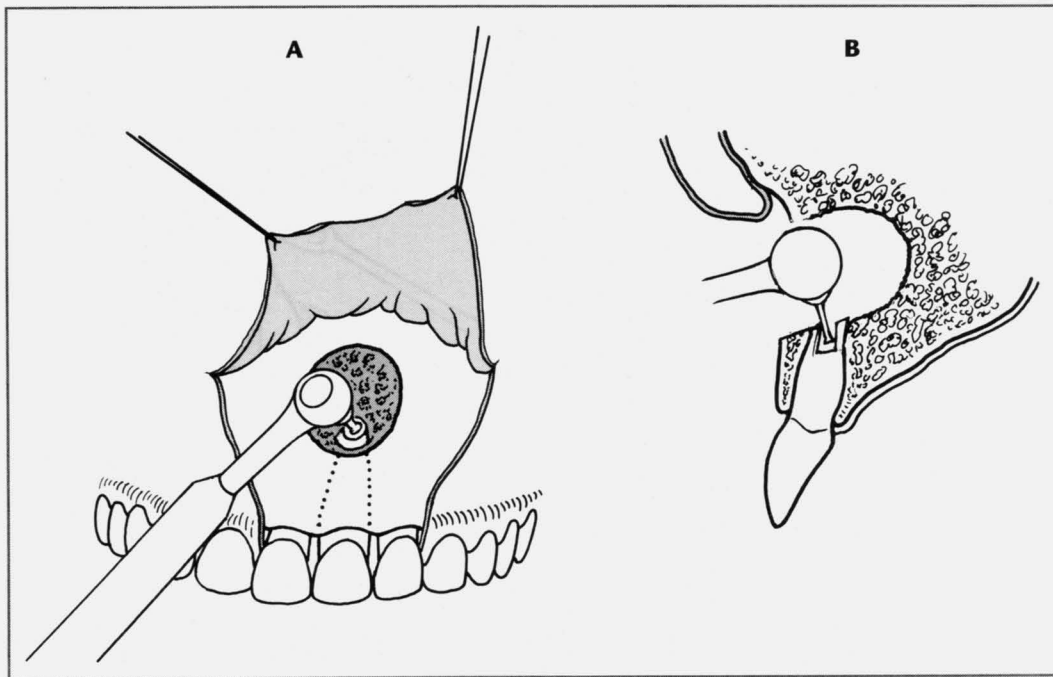


FIG. 17-21 Root end preparation. Microhandpiece with small round or inverted cone bur should prepare several millimeters into root. A, Frontal view. B, Cross-section.

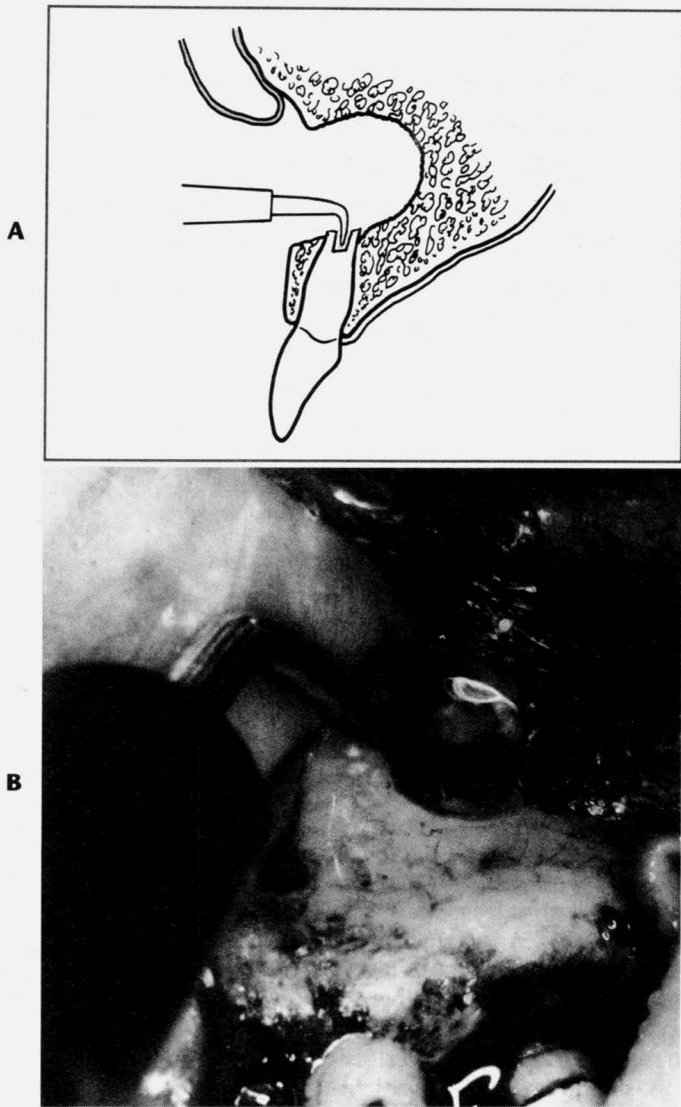


FIG. 17-22 A, Ultrasonic tips are good alternative for root end preparation. B, These permit preparation with better control and less root removal.

Indications

Procedural errors. Procedural errors are openings through the lateral root surface created by the operator, typically during access, canal instrumentation, or post space preparation (Fig. 17-25). The result is perforation, which presents a difficult surgical challenge, more so than repairing damage to a root end. Perforations often require restorative management and completion of the root canal treatment, usually in conjunction with the surgical phase. The location of the perforation influences success; some are virtually inaccessible. If the defect is on the interproximal, in the furcation, or close to adjacent teeth or to the lingual, adequate repair may not be possible or is compromised. Defects that are too far posterior (particularly on the distal or lingual aspects) may be very difficult to reach. The nature and location of the perforation should be determined with angled radiographs before the decision is made whether to

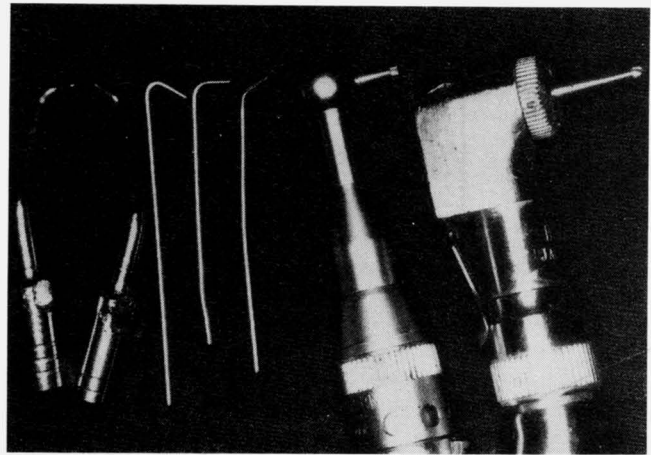


FIG. 17-23 Ultrasonic preparation tips are available in several designs and shapes for different applications. On right are micro-handpiece and conventional handpiece.

repair surgically, to remove the involved root, or to extract.²⁴

Resorptive perforations. Resorptive perforations may be internal or external in origin (Fig. 17-26), resulting in a communication between pulp and periodontium. A more serious defect is one that extends to include cervical exposure to the oral cavity.

Resorption occurs for several reasons, but most cases include inflammation from an irritant. These irritants include sequelae to trauma, internal bleaching procedures, orthodontic tooth movement, restorative procedures, or other factors causing pulp or periradicular inflammation. Occasionally, resorptions are idiopathic, with no demonstrable cause.

As with procedural errors, the considerations as to treatability and surgical approach are similar.

Contraindications

Anatomic considerations. Consideration must be given to structural impediments to a surgical approach. Few exist, and most can be managed or avoided. Included are various nerve and vessel bundles and bony structures, such as the external oblique ridge.

Location of perforation. As mentioned previously, the defect must be accessible surgically. This means the clinician must be able to locate and, ideally, to readily visualize the surgical area.

Accessibility. A handpiece or an ultrasonic instrument generally is necessary to prepare the defect. Therefore the defect must be reachable, without impedance by structures or by lack of visibility.

Considerations

Surgical approach. Repair presents a unique set of problems. The defect may wrap from facial to proximal to lingual, creating not only difficulties in visualization but also problems with access and hemostasis and material placement. A general guideline is that the defect is larger and more complex than it appears on a radiograph.

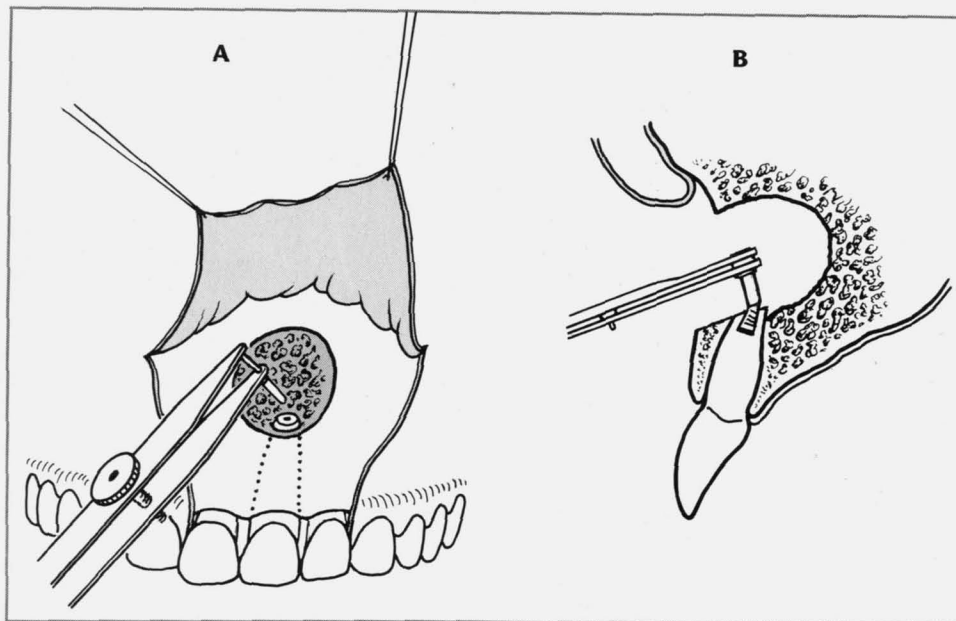


FIG. 17-24 Special small amalgam carriers are used to place material, which is then packed with small condensers. Other cement type of materials are carried and compacted with paddles and bur-nishers. **A**, Frontal view. **B**, Cross-section.

Generally, the defect must be enlarged to provide a sound cavosurface margin and to avoid knife-edge margins. Occasionally, the repair is internal (from inside the canal), with material being extruded through the defect. The excess is removed and contoured with burs or sharp instruments. The objective is to seal and stabilize the defect with a restorative material. If a post or other material is perforating the root, it must be reduced with burs to within root structure and a cavity prepared. Then the defect is restored with one of the materials mentioned previously.

Repair material. External repair is often with amalgam or, if the field is dry, glass ionomer or dentin-bonding agent with composite resin. Other materials are suitable, such as MTA or Super EBA; these have not had the test of time but are promising materials.²⁵ MTA, in particular, shows favorable biologic properties.²⁶ The same considerations of physical and biologic properties, as just described, apply. One major difference is in the repair of a defect that will be exposed to oral fluids; Super EBA or MTA are contraindicated, because they will gradually wash out of the cavity. More stable materials—composite resins, amalgam, or glass ionomers—are preferred. Certain glass ionomers have promise and have indicated the possibility of tissue attachment to the material, although long-term studies are lacking.

Prognosis. Repairs in the cervical third or furcation in particular have the poorest prognosis. Communication often is eventually established with the junctional epithelium, which will result in periodontal breakdown, loss of attachment, and pocket formation. This would mean that a periodontal procedure (e.g., crown lengthening) would be required in conjunction with the defect repair.

A defect in the middle or apical third that is properly prepared and sealed will have a very good long-term prognosis.

Surgical Procedure

After the basic approaches with periapical surgery, the next step is to perform corrective surgery. Flap designs are similar but are more limited. A sulcular incision is usually required, with at least one vertical incision to form a three-cornered flap. A full-thickness flap is reflected and bone removed to expose the defect (Fig. 17-27). Bone removal must be adequate to allow maximal visualization and access. If possible, a rim of cervical bone should be retained to support the flap and possibly to enhance reattachment; this is frequently not possible with cervical defects.

The preparation of a facial or lingual defect is similar to that of a class I cavity preparation (Fig. 17-28). An interproximal defect resembles a class II preparation, with an opening from the facial (or lingual) aspect and including the interproximal wall but leaving a lingual wall (if possible).

The facial or lingual cavity is then filled by direct placement of the material. A class II (i.e., interproximal, or furcation) cavity requires a matrix. For example, an amalgam matrix band is held in position with fingers or a wedge, then material is packed into the cavity preparation. This matrix is less critical if amalgam is not used. The material is carved flush with the cavity margins. Flap replacement, suturing, and digital pressure are as described earlier. Suture removal should be within 3 to 6 days. Postoperative instructions are similar to those after periapical surgery.

HEALING

Healing after endodontic surgery is rapid because most tissues being manipulated are healthy, with a good blood supply, and tissue replacement enables repair by primary intention.²⁷ Both soft tissues (i.e., periosteum, gingiva, alveolar mucosa, periodontal ligament) and hard tissues

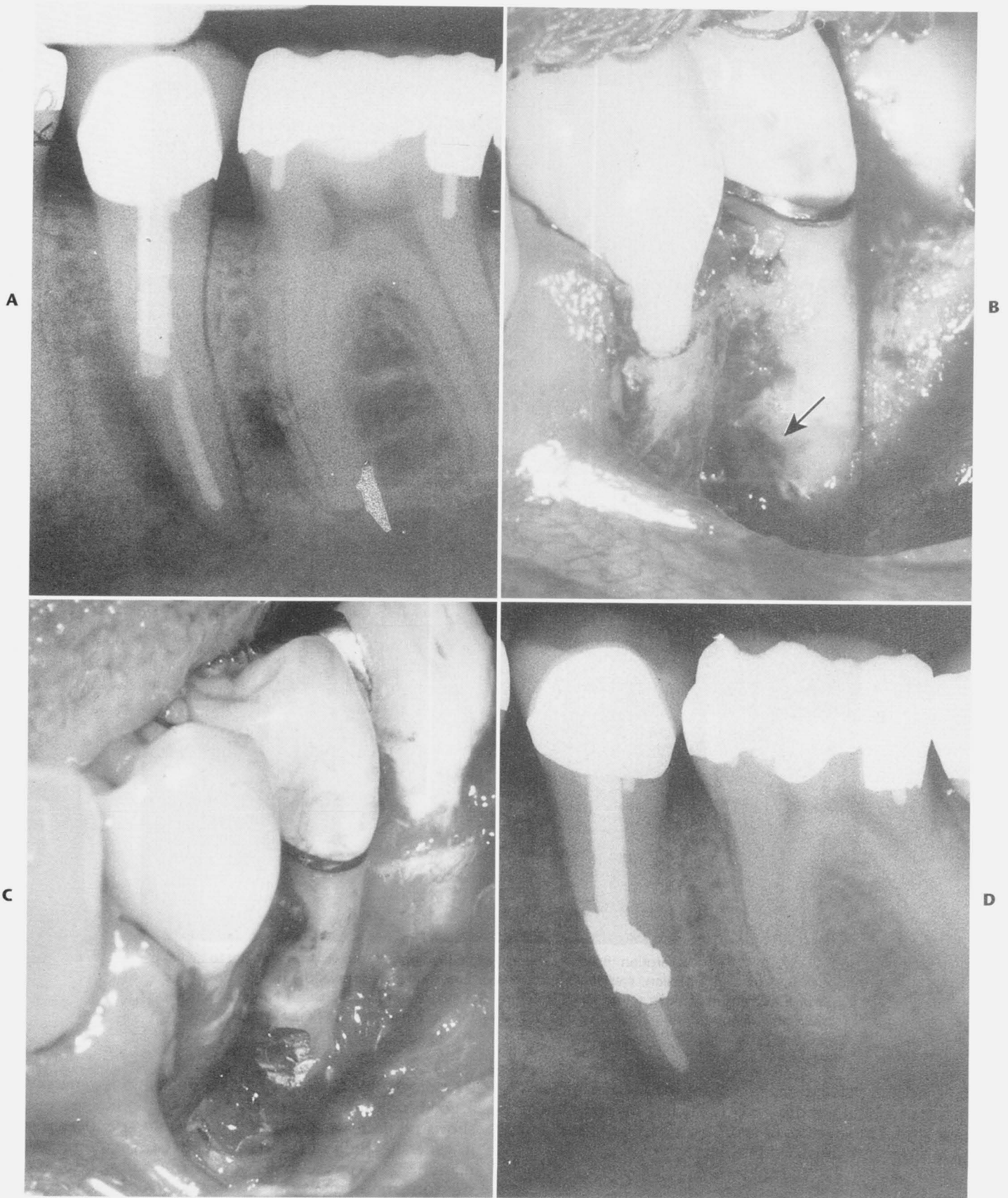

FIG. 17-25 Postperforation repair. A, Lesion developing lateral to off-centered post suggests perforation that (B) is identified (*arrow*) on flap reflection. C, Post is reduced to within root and cavity filled with amalgam (D).

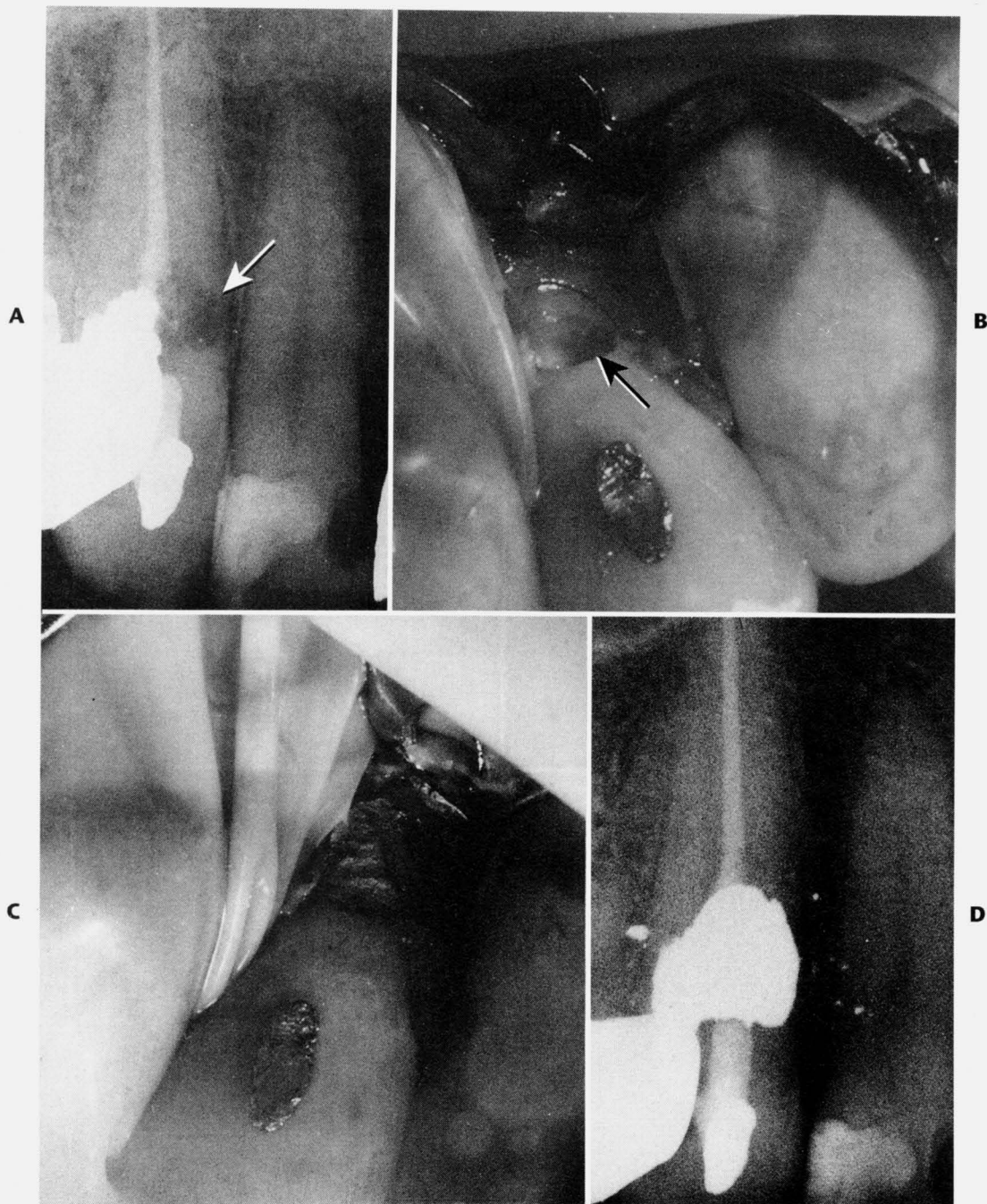


FIG. 17-26 External resorption repair. **A**, Mesially angled radiograph shows defect (*arrow*) to be lingual. **B**, After flap reflection, crestal bone reduction, and rubber dam isolation, defect is prepared (*arrow*). Margins must be in sound tooth structure. **C**, Cavity is filled with amalgam and flap apically positioned. **D**, Long-term radiographic and clinical evaluation is necessary; at times, resorption recurs.

(i.e., dentin, cementum, bone) are involved. Time and mode of healing varies with each, but involve similar processes. The specifics of short-term healing of soft and hard tissues are discussed in Chapter 4.

RECALL

Recall evaluations to assess long-term healing are important. Some failures after surgery are evidenced only

by radiographic findings. A 1-year follow-up is generally a good indicator. If, after 1 year, radiographic evidence shows no decrease in lesion size or lesion size increases, it generally indicates a failure and persistent inflammation.²⁸ A decrease in lesion size (indicating hard tissue formation) may lead to complete healing and requires evaluation at 6 to 12 months. Of course, persistent symptoms, such as pain or swelling (or both), presence of sinus tract, deep probing defects, or other adverse

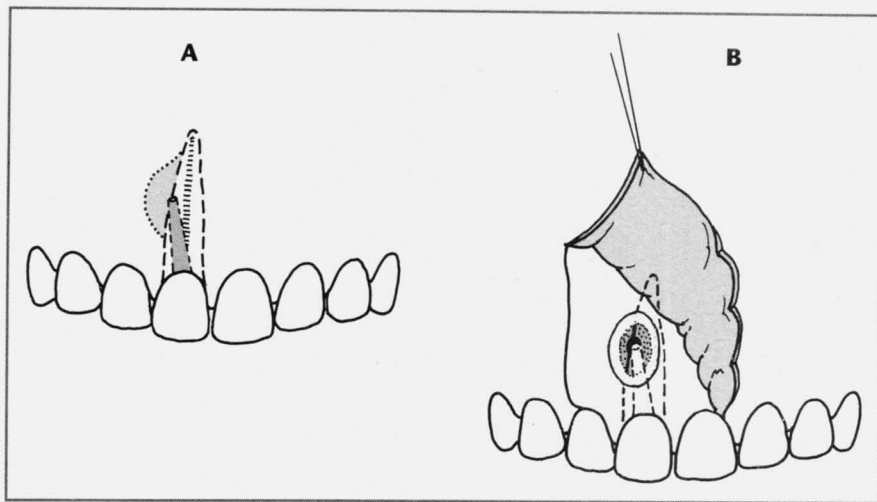


FIG. 17-27 A, Misdirected post is perforating distally. B, Full mucoperiosteal (i.e., sulcular incision) three-corner flap is raised and bone removed to expose defect.

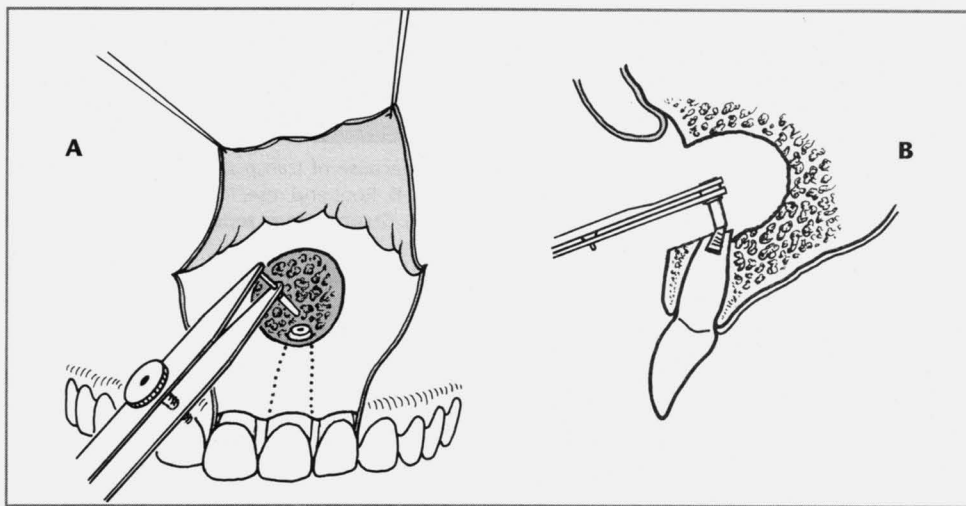


FIG. 17-28 A, Post is reduced to well within root, and cavity is prepared. B, In this cross-section through defect, a lingual wall to the preparation is evident.

findings would also indicate failure. Healing by scar tissue after surgery occurs primarily in the maxillary incisors (Fig. 17-29). This is unusual and has a unique radiographic appearance with an irregular distinct outline, often separated from the root end. Healing by scar tissue is considered to be a successful outcome.²⁹

Frequently, structures over the apex do not regenerate to a normal appearance. At times, connective tissue or bony arrangements leave a slightly "widened" periodontal ligament space. This should have relatively distinct, corticated margins and not be diffuse (which indicates inflammation and a failure).³⁰

ADJUNCTS

Some of the newer devices and materials have enhanced and, in some cases, improved surgical procedures. These include the light and magnification devices and techniques of guided tissue regeneration.

Light and Magnification Devices

Surgical microscope. Relatively recently the microscope has been adapted and used for surgery, as well as for other diagnostic and treatment procedures in endodontics (Fig. 17-30).³¹ Advantages of the microscope include magnification and in-line illumination. They also can be adapted for videotaping and to transmit the image to a television monitor for direct viewing or recording. These enhance the view of the surgical field, help identify previously undetected structures, and facilitate surgical procedures. Although some clinicians advocate and are excited about the use of these microscopes, as yet there have not been demonstrated substantial clinical benefits through long-term controlled studies. However, some evidence suggests that the microscope use improves on surgical techniques and short-term outcomes.

Fiber optics. A new system, known as *endoscopy*, is available that uses a very small, flexible fiber bundle that contains both a light and an optic system. The optics are

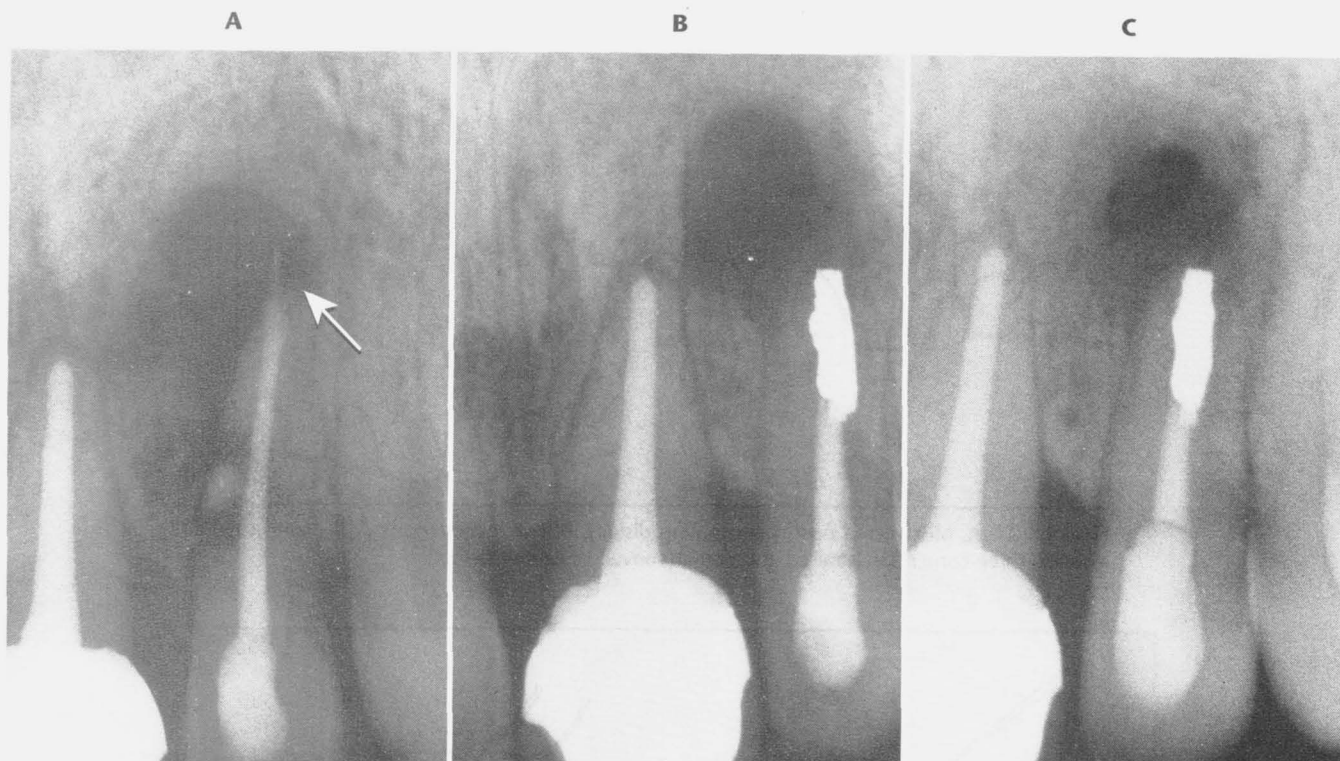

FIG. 17-29 Healing by scar tissue. A, Failed treatment because of transportation and perforation, leaving area of canal (arrow) undébrided and unobturated. B, Root end resection, curettage, and root end filling. C, After 2 years, an area of radiolucency is seen. Sharp border, separation from apex, and distinct radiolucency show this to be a scar.

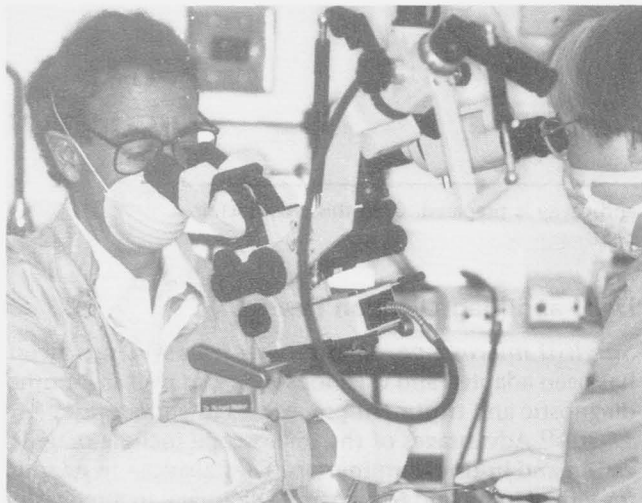

FIG. 17-30 Surgical microscope has been adapted for endodontic procedures, including surgery. Magnification and in-line illumination enhance visualization for diagnosis and treatment. Add-on binoculars for dental assistant are useful adjunct.

connected to a monitor that permits visualization of precise details of the surgical site.³² This system also gives the clinician the option of videotaping and recording procedures.

Guided Tissue Regeneration

Originally intended for periodontal surgery, guided tissue regeneration also has been applied to endodontic surgery. The membranes used in this procedure are applied where defects have extended to cervical margins or as a covering of large defects surrounded by bone.³³ These membranes, particularly those that are resorbable, may prove useful in selected situations. However, evidence indicating their long-term effectiveness in endodontic surgery is incomplete (although these membranes have been shown to enhance bone regeneration).³⁴ Whether these result in long-term, substantial benefits has not been demonstrated.

Bone Augmentation

Various substances have been placed in the periradicular surgical cavities in the attempt to enhance bony healing. Because of the location of the cavity, and because most of the periphery is encased in bone or periosteum, bone regeneration is predictable. Such augmentation materials are of no benefit and should not be placed.

WHEN TO CONSIDER REFERRAL

Although many of the procedures presented in this chapter appear relatively straightforward, endodontic surgery is often complex and difficult to perform. Clinicians

should carefully consider the problems before undertaking such surgeries.

Training and Experience

Most generalists do not have the advanced training, including didactic and clinical experience, necessary to perform surgical procedures. These procedures are a unique discipline and require special skills in diagnosis, treatment planning, and management; they also require a special armamentarium. Also important are skill in long-term evaluation and resolving of failures or other complications. With increased emphasis on standards of care and litigation problems, coupled with the availability of experienced specialists, general dentists should consider their own expertise as it relates to case difficulty. These procedures are often the last hope of tooth retention. Lack of training may result in inadequate or inappropriate surgery and loss of a particular tooth and possible damage to other structures.³⁵

Determining the Cause of Root Canal Treatment Failure

Two steps are critical to success, particularly if surgery is being considered: (1) *identification of the cause of failure* and (2) *design of the treatment plan*. Frequently, surgery is not the best choice but when necessary must be done appropriately. A specialist is better able to identify these causes and approach their resolution. If the cause of the failure cannot be identified, these cases must be considered for referral.

Surgical Difficulties

In many situations, surgical accessibility is limited and even hazardous. For example, the neurovascular bundle near mandibular posterior teeth and maxillary palatal root apices presents the potential for creating paresthesia, excessive hemorrhage, or both. Complicating structures include overlying bone throughout the mandible and in the palate, the frena and other muscle attachments, fenestrations of cortical bone, and sinus cavities. These structures require care and the proper use of instruments and surgical skill.

In summary, most of the procedures discussed in this chapter require greater training and experience than are provided in an undergraduate dental education program. If the clinician has not had additional postgraduate training and experience, referral must be considered.

REFERENCES

1. Grung B, Mølven O, Halse A: Periapical surgery in a Norwegian county hospital: follow-up findings of 477 teeth, *J Endod* 16:411, 1990.
2. Allen RK, Newton CW, Brown CE: A statistical analysis of surgical and nonsurgical endodontic retreatment cases, *J Endod* 15:261, 1989.
3. Houck V et al: Effect of trephination on postoperative pain and swelling in symptomatic necrotic teeth, *Oral Surg Oral Med Oral Path Oral Radiol Endod* 90:507, 2000.
4. Moiseiwitsch JR, Trope M: Nonsurgical root canal therapy treatment with apparent indications for root-end surgery, *Oral Surg Oral Med Oral Path Oral Radiol Endod* 86:335, 1998.
5. Danin J et al: Outcomes of periradicular surgery in cases with apical pathosis and untreated canals, *Oral Surg Oral Med Oral Path Oral Radiol Endod* 87:227, 1999.
6. Neaverth EJ, Burg HA: Decompression of large periapical cystic lesions, *J Endod* 8:175, 1982.
7. Kvist T, Tut C: Postoperative discomfort associated with surgical and nonsurgical endodontic retreatment, *Endod Dent Traumatol* 16:71, 2000.
8. Kramper BJ et al: A comparative study of the wound healing of three types of flap design used in periapical surgery, *J Endod* 10:17, 1984.
9. Davis W, Oakley J, Smith E: Comparison of the effectiveness of etidocaine and lidocaine as local anesthetic agents during oral surgery, *Anesth Prog* 31:159, 1984.
10. Battrum DE, Gutmann JL: Implications, prevention, and management of subcutaneous emphysema during endodontic treatment, *Endod Dent Traumatol* 11:109, 1995.
11. Fister J, Gross BD: A histologic evaluation of bone response to bur cutting with and without water coolant, *Oral Surg Oral Med Oral Pathol* 49:105, 1980.
12. Lin LM, Gaengler P, Langeland K: Periradicular curettage, *Int Endod J* 29:220, 1996.
13. Lemon R, Steele P, Jeansonne B: Ferric sulfate hemostasis: effect on osseous wound healing, *J Endod* 19:170, 1993.
14. Ibarrola J et al: Osseous reactions to three hemostatic agents, *J Endod* 11:75, 1985.
15. Gray G et al: Quality of root-end preparations using ultrasonic and rotary instrumentation in cadavers, *J Endod* 26:281, 2000.
16. Peters CI, Peters OA, Barbakow F: An in vitro study comparing root-end cavities prepared by diamond-coated and stainless steel ultrasonic retrotips, *Int Endod J* 34:142, 2001.
17. Testori T et al: Success and failure in periradicular surgery: a longitudinal retrospective analysis, *Oral Surg Oral Med Oral Path Oral Radiol Endod* 87:493, 1999.
18. Trope M et al: Healing of apical periodontitis in dogs after apicoectomy and retrofilling with various filling materials, *Oral Surg Oral Med Oral Pathol Oral Radiol Endod* 81:221, 1996.
19. Torabinejad M et al: Histologic assessment of mineral trioxide aggregate as a root-end filling in monkeys, *J Endod* 23:225, 1997.
20. Torabinejad M et al: Investigation of mineral trioxide aggregate for root-end filling in dogs, *J Endod* 21:603, 1995.
21. Johnson B: Considerations in the selection of a root-end filling material, *Oral Surg Oral Med Oral Path Oral Radiol Endod* 87:398, 1999.
22. Rud J, Rud V, Munksgaard EC: Periapical healing of mandibular molars after root-end sealing with dentine-bonded composite, *Int Endod J* 34:285, 2001.
23. Fouad A, Rivera E, Walton R: Penicillin as a supplement in resolving the localized acute apical abscess, *Oral Surg Oral Med Oral Path Oral Radiol Endod* 81:590, 1996.
24. Fuss Z, Trope M: Root perforations: classification and treatment choices based on prognostic factors, *Endod Dent Traumatol* 12:255, 1996.
25. Lee S, Monsef M, Torabinejad M: Sealing ability of a mineral trioxide aggregate for repair of lateral root perforations, *J Endod* 19:541, 1993.
26. Holland R et al: Mineral trioxide aggregate repair of lateral root perforations, *J Endod* 27:281, 2001.

27. Selvig, K, Torabinejad M: Wound healing after mucoperiosteal surgery in the cat, *J Endod* 22:507, 1996.
28. Rud J, Andreassen J, Möller J: A multivariate analysis of the influence of various factors upon healing after endodontic surgery, *Int J Oral Surg* 1:258, 1972.
29. Mölven O, Halse A, Grung B: Incomplete healing (scar tissue) after periapical surgery: radiographic findings 8 to 12 years after treatment, *J Endod* 22:264, 1996.
30. Mölven O, Halse A, Grung B: Surgical management of endodontic failures: indications and treatment results, *Int Dent J* 46:33, 1991.
31. Mines P et al: Use of the microscope in endodontics: a report based on a questionnaire, *J Endod* 25:755, 1999.
32. Bahcall J, DiFiore P, Poulakidas T: An endoscopic technique for endodontic surgery, *J Endod* 25:132, 1999.
33. Rankow H, Krasner P: Endodontic applications of guided tissue regeneration in endodontic surgery, *J Endod* 22:34, 1996.
34. Douthitt, JC, Gutmann J, Witherspoon D: Histologic assessment of healing after the use of a bioresorbable membrane in the management of buccal bone loss concomitant with periradicular surgery, *J Endod* 27:404, 2001.
35. Rahbaran S et al: Comparison of clinical outcome of periapical surgery in endodontic and oral surgery units of a teaching dental hospital: a retrospective study, *Oral Surg Oral Med Oral Pathol Oral Radiol Endod* 91:700, 2001.

BIBLIOGRAPHY

- Andreassen J, Rud J: Correlation between histology and radiography in the assessment of healing after endodontic surgery in 70 cases, *Int J Oral Surg* 1:161, 1972.
- El Deeb, ME, Tabibi A, Jensen MR Jr: An evaluation of the use of amalgam, Cavit and calcium hydroxide in the repair of furcation perforations, *J Endod* 8:459, 1982.
- El-Swiah JM, Walker RT: Reasons for apicectomies: a retrospective study, *Endod Dent Traumatol* 12:185, 1996.
- Forbes G: Apical microsurgery for failed endodontics, *Atlas Oral Maxillofac Surg Clin North Am* 8:1, 2000.
- Gutmann JL, Harrison JW: Posterior endodontic surgery: anatomical consideration and clinical techniques, *Int Endod J* 18:8, 1985.

Gutmann JL, Harrison JW: *Surgical endodontics*, Boston, 1994, Blackwell Scientific.

Gutmann JL et al: *Problem solving in endodontics: prevention, identification, and management*, ed 3, St Louis, 1997, Mosby.

Harrison JW, Jurosky KA: Wound healing in the periodontium following endodontic surgery. I. The incisional wound, *J Endod* 17:425, 1991.

Harrison JW, Jurosky KA: Wound healing in the periodontium following endodontic surgery. II. The dissectional wound, *J Endod* 17:544, 1991.

Harrison JW, Jurosky KA: Wound healing in the tissues of the periodontium following endodontic surgery. III. The osseous excisional wound, *J Endod* 18:76, 1992.

Lubow RM, Wayman BE, Cooley RL: Endodontic flap design: analysis and recommendation for current usage, *Oral Surg Oral Med Oral Pathol* 58:207, 1984.

McDonald N, Torabinejad M: Surgical endodontics. In Walton R, Torabinejad M, editors: *Principles and practice of endodontics*, ed 3, Philadelphia, 2002, WB Saunders.

Morgan LA, Marshall JG: A scanning electron microscopic study of in vivo ultrasonic root-end preparations, *J Endod* 25:567, 1999.

Pantschev A, Carlsson AP, Andersson L: Retrograde root filling with EBA cement or amalgam: a comparative clinical study, *Oral Surg Oral Med Oral Pathol* 78:101, 1994.

Sauveur G et al: The control of haemorrhage at the operative site during periradicular surgery, *Int Endod J* 32:225, 1999.

Skoner JR et al: Blood mercury levels with amalgam retroseals: a longitudinal study, *J Endod* 22:140, 1996.

Stromberg T, Hasselgren G, Bergstedt H: Endodontic treatment of traumatic root perforations in man: a clinical and roentgenological follow-up study, *Sven Tandlak Tidsskr* 65:457, 1972.

Torabinejad M, Chivian N: Clinical applications of mineral trioxide aggregate, *J Endod* 25:197, 1999.

von Arx T, Walker WA III: Microsurgical instruments for root-end cavity preparation following apicoectomy: a literature review, *Endod Dent Traumatol* 16:47, 2000.

Witherspoon D, Gutmann J: Haemostasis in periradicular surgery, *Int Endod J* 29:135, 1996.

Zuolo ML, Ferreira MOF, Gutmann JL: Prognosis in periradicular surgery: a clinical prospective study, *Int Endod J* 33:91, 2000.